



Published in final edited form as:

*Support Care Cancer*. 2016 June ; 24(6): 2793–2805. doi:10.1007/s00520-016-3153-y.

## Low-level laser therapy/photobiomodulation in the management of side effects of chemoradiation therapy in head and neck cancer: part 2: proposed applications and treatment protocols

Judith A. E. M. Zecha<sup>1</sup>, Judith E. Raber-Durlacher<sup>1,2</sup>, Raj G. Nair<sup>3</sup>, Joel B. Epstein<sup>4,5</sup>, Sharon Elad<sup>6</sup>, Michael R. Hamblin<sup>7,8,9</sup>, Andrei Barasch<sup>10</sup>, Cesar A. Migliorati<sup>11</sup>, Dan M. J. Milstein<sup>1</sup>, Marie-Thérèse Genot<sup>12</sup>, Liset Lansaat<sup>13</sup>, Ron van der Brink<sup>5</sup>, Josep Arnabat-Dominguez<sup>15</sup>, Lisette van der Molen<sup>13</sup>, Irene Jacobi<sup>13</sup>, Judi van Diessen<sup>14</sup>, Jan de Lange<sup>1</sup>, Ludi E. Smeele<sup>1,13</sup>, Mark M. Schubert<sup>16</sup>, and René-Jean Bensadoun<sup>17</sup>

Judith A. E. M. Zecha: j.zecha@amc.uva.nl; Judith E. Raber-Durlacher: j.e.raberdurlacher@amc.uva.nl; Raj G. Nair: r.nair@griffith.edu.au; Joel B. Epstein: joel.epstein@cshs.org; Sharon Elad: SElad@URMC.Rochester.edu; Michael R. Hamblin: hamblin@helix.mgh.harvard.edu; Andrei Barasch: barasaff@cs.com; Cesar A. Migliorati: miglioni@uthsc.edu; Dan M. J. Milstein: D.M.Milstein@amc.uva.nl; Marie-Thérèse Genot: mtgenot@skynet.be; Liset Lansaat: l.lansaat@nki.nl; Ron van der Brink: RVanderbrink@coh.org; Josep Arnabat-Dominguez: joseparnabat@ub.edu; Lisette van der Molen: l.vd.molen@nki.nl; Irene Jacobi: i.jacobi@nki.nl; Judi van Diessen: j.v.diessen@nki.nl; Jan de Lange: j.delange@amc.uva.nl; Ludi E. Smeele: l.smeele@nki.nl; Mark M. Schubert: mschuber@seattlecca.org; René-Jean Bensadoun: renejean.bensadoun@che-nice.com

<sup>1</sup>Department of Oral and Maxillofacial Surgery, Academic Medical Center, University of Amsterdam, Meibergdreef 9, 1105, AZ Amsterdam, The Netherlands <sup>2</sup>Department of Medical Dental Interaction and Department of Periodontology, Academic Centre for Dentistry Amsterdam (ACTA), University of Amsterdam and VU University, P.O. Box 22660 1100 DD, Amsterdam, the Netherlands <sup>3</sup>Oral Medicine Oral Pathology and Human Diseases, Menzies Health Institute Queensland and Oral Medicine Consultant, Department of Haematology and Oncology/Cancer Services, Gold Coast University Hospital, Queensland Health, Queensland, Australia <sup>4</sup>Samuel Oschin Comprehensive Cancer Institute, Cedars-Sinai Medical Center, Los Angeles, CA 90048, USA <sup>5</sup>Division of Otolaryngology and Head and Neck Surgery, City of Hope, Duarte, CA 91010, USA <sup>6</sup>Division of Oral Medicine, Eastman Institute for Oral Health, and Wilmot Cancer Center, University of Rochester Medical Center, Rochester, NY 14620, USA <sup>7</sup>Wellman Center for Photomedicine, Massachusetts General Hospital, Boston, MA 02114, USA <sup>8</sup>Department of Dermatology, Harvard Medical School, Boston, MA 02115, USA <sup>9</sup>Harvard-MIT Division of Health Science and Technology, Cambridge, MA 02139, USA <sup>10</sup>Division of Oncology, Weill Cornell

Correspondence to: René-Jean Bensadoun, renejean.bensadoun@che-nice.com.

**Disclaimer** This article is based on a narrative review of existing data and the clinical observations of an international multidisciplinary panel of clinicians and researchers with expertise in the area of supportive care in cancer and/or PBM clinical application and dosimetry. This article is informational in nature. As with all clinical materials, this paper should be used with the clear understanding that continued research and practice could result in new insights and recommendations. The review reflects the collective opinion and as such does not necessarily represent the opinion of any individual author. In no event shall the authors be liable for any decision made or action taken in reliance on the proposed protocols.

**Disclosures** Judith A.E.M. Zecha, Andrei Barasch, Sharon Elad, Steven Sonis, Cesar A. Migliorati, Marie-Thérèse Genot, Dan M.J. Milstein, Liset Lansaat, Irene Jacobi, Judi van Diessen, Jan. de Lange, Ludi E. Smeele and Mark M. Schubert have no disclosures relevant to this work to report.

Judith E. Raber-Durlacher, Raj G. Nair, Joel B. Epstein, Ron van der Brink, Josep Arnabat Dominguez, and Rene-Jean Bensadoun have received travel expenses and hotel accommodation for the founding meeting of iGLOB from THOR Photomedicine Ltd., UK. Raj Nair has received an honorarium from THOR, UK. Michael R Hamblin was supported by US NIH grant R01AI050875.

Medical Center, New York, NY, USA <sup>11</sup>Department of Diagnostic Sciences and Oral Medicine, Director of Oral Medicine, College of Dentistry, University of Tennessee Health Science Center, 875 Union Ave. Suite N231, Memphis, TN 38163, USA <sup>12</sup>Laser Therapy Unit, Institut Jules Bordet, Centre des Tumeurs de l'Université Libre de Bruxelles, Brussels, Belgium <sup>13</sup>Antoni van Leeuwenhoek Department of Head and Neck Oncology and Surgery, Netherlands Cancer Institute, Amsterdam, the Netherlands <sup>14</sup>Antoni van Leeuwenhoek Department of Radiation Oncology, Amsterdam, Netherlands Cancer Institute, Amsterdam, the Netherlands <sup>15</sup>Department of Oral Surgery, Faculty of Dentistry, University of Barcelona, Barcelona, Spain <sup>16</sup>Seattle Cancer Care Alliance (SCCA), Oral Medicine, 825 Eastlake Ave E Ste G6900, Seattle, WA 98109, USA <sup>17</sup>World Association for Laser Therapy (WALT) Scientific Secretary, Centre de Haute Energie (CHE), 10 Bd Pasteur, 06000 Nice, France

## Abstract

**Purpose**—There is a large body of evidence supporting the efficacy of low-level laser therapy (LLLT), more recently termed photobiomodulation (PBM) for the management of oral mucositis (OM) in patients undergoing radiotherapy for head and neck cancer (HNC). Recent advances in PBM technology, together with a better understanding of mechanisms involved and dosimetric parameters may lead to the management of a broader range of complications associated with HNC treatment. This could enhance patient adherence to cancer therapy, and improve quality of life and treatment outcomes. The mechanisms of action, dosimetric, and safety considerations for PBM have been reviewed in part 1. Part 2 discusses the head and neck treatment side effects for which PBM may prove to be effective. In addition, PBM parameters for each of these complications are suggested and future research directions are discussed.

**Methods**—Narrative review and presentation of PBM parameters are based on current evidence and expert opinion.

**Results**—PBM may have potential applications in the management of a broad range of side effects of (chemo)radiation therapy (CRT) in patients being treated for HNC. For OM management, optimal PBM parameters identified were as follows: *wavelength*, typically between 633 and 685 nm or 780–830 nm; *energy density*, laser or light-emitting diode (LED) output between 10 and 150 mW; *dose*, 2–3 J (J/cm<sup>2</sup>), and no more than 6 J/cm<sup>2</sup> on the tissue surface treated; *treatment schedule*, two to three times a week up to daily; *emission type*, pulsed (<100 Hz); and *route of delivery*, intraorally and/or transcutaneously. To facilitate further studies, we propose potentially effective PBM parameters for prophylactic and therapeutic use in supportive care for dermatitis, dysphagia, dry mouth, dysgeusia, trismus, necrosis, lymphedema, and voice/speech alterations.

**Conclusion**—PBM may have a role in supportive care for a broad range of complications associated with the treatment of HNC with CRT. The suggested PBM irradiation and dosimetric parameters, which are potentially effective for these complications, are intended to provide guidance for well-designed future studies. It is imperative that such studies include elucidating the effects of PBM on oncology treatment outcomes.

## Keywords

Low-level laser therapy; Low-level light therapy; Photobiomodulation; Mucositis; Orofacial complications; Chemotherapy; Radiation therapy; Head and neck cancer; LLLT; PBM

---

## Introduction

Nearly all patients with advanced head and neck cancer (HNC) suffer orofacial, oropharyngeal, and neck complications from treatment with radiation therapy (RT) or chemoradiotherapy (CRT) [1].

The severity of complications varies depending upon the type and site of the tumor, mode and intensity of therapies involved, and individual patient characteristics. Nevertheless, in most patients, complications are associated with significant morbidity and mortality resulting in increased use of health-care resources and may compromise patient adherence to cancer therapy protocols resulting in suboptimal outcomes. Most patients develop multiple complications, which result in a significant burden of illness with negative impact on quality of life (QoL) [1–5].

Supportive care addressing these complications must continue from initial diagnosis of HNC, through treatment and survival. However, many interventions have limitations and are primarily palliative in nature [6].

Among the presently available supportive care measures, the use of photobiostimulation (PBM) has shown significant promise. PBM refers to various light energies such as low-level laser therapy (LLLT) and light-emitting diode (LED) and visible light (see part 1).

Systematic reviews have suggested efficacy of PBM for oral mucositis (OM) management in myeloablative hematopoietic stem cell transplant (HSCT) recipients and in HNC patients [7–12]. However, recent advances in PBM application and PBM devices, together with a better understanding of the pathobiology of HNC treatment-induced complications, may lead to a broader range of indications for PBM in the management of these problems.

A task force consisting of an international multidisciplinary panel of clinicians and researchers with expertise in the area of supportive care in cancer and/or PBM clinical application and dosimetry was formed. The mission of this group is to identify potential indications for PBM in the management of side effects of cancer therapy, design of PBM study protocols, identify validated outcome measures, and test the efficacy and safety of proposed protocols for the management of complications related to cancer therapy.

Part 1 of this review addressed mechanisms of action, dosimetric, and safety considerations. This paper (part 2) discusses the following: (i) selected oral, oropharyngeal, facial, and neck complications of treatment for HNC, in which PBM may have potential for prophylaxis and/or treatment; (ii) PBM parameters for prophylaxis and therapy to mitigate these complications based on current evidence and knowledge; and (iii) directions of future research related to the use of PBM in HNC.

## **PBM for the management of orofacial and neck complications of cancer therapy**

The following paragraphs summarize selected acute and chronic complications associated with HNC therapy and the literature relevant to the use of PBM for the management of these complications.

For each of these complication, we propose prophylactic and therapeutic PBM protocols based on evidence derived from the literature and expert opinion (Table 1). These protocols are intended to provide clinical guidance and to serve as a starting point for continuing research. Please see part 1 of this review for discussion of mechanism of action and of safety of PBM.

### **Oral mucositis**

Oral mucositis affects virtually all patients undergoing CRT for HNC. Clinically, the manifestations of OM form a continuum, with erythematous mucosal changes when mild, and, ulcerative lesions that expose the submucosa when severe. The detrimental effects of OM upon QoL and functional status are significant [2].

The current understanding of the pathogenesis of OM is largely based on animal models, which document the multi-factorial nature of this inflammatory condition and have implicated a cascade of interrelated events in multiple tissue compartments. These observations lead to the five-phase model of OM, based on the sequence of events following cytotoxic treatment [13]. Inflammation induced by the formation of excessive reactive oxygen species (ROS) and activation of nuclear factor kappa B (NF- $\kappa$ B) are the key factors in its pathobiology [14]. Subsequent studies implicated microvascular injury, formation of proinflammatory cytokines, host–microbiome interactions, and extracellular matrix alterations in mucositis pathogenesis [15]. In addition, epidermal growth factor receptor (EGFR) inhibitors and tyrosine kinase receptor inhibitors (TKI) administered as single drugs or combined with CRT may enhance OM or cause additional symptoms [16, 17]. Effective management options for OM are limited [18], and pain control is typically inadequate [2].

A Cochrane meta-analysis concluded that PBM may prevent severe OM [7]. A systematic review and meta-analysis of 11 randomized controlled trials (RCTs) in HNC patients treated with (chemo)radiation therapy concluded that there was consistent evidence that PBM applied with doses of 1–6 J per point reduced OM prevalence, severity, and duration, and its associated pain [9]. Another meta-analysis including RCTs in various cancer treatment settings showed that PBM reduced OM risk and decreased its severity and duration [10]. The efficacy appeared to be similar for red [630–670 nm] and NIR (780–830 nm) light, although the optimal doses may vary between these wavelengths. Similarly, a systematic review and meta-analysis including 18 RCTs reported that prophylactic PBM reduced severe OM and associated pain in patients treated for HNC or undergoing HSCT [12]. The Clinical Practice Guidelines of the Multinational Association of Supportive Care in Cancer and International Society for Oral Oncology (MASCC/ISOO) Mucositis Study Group found evidence to recommend PBM for the prevention of OM in HSCT recipients conditioned with high-dose

chemotherapy, with or without total body irradiation, and to suggest a role for patients treated with RT for HNC [11, 18]. Evidence was derived from high-quality studies using specific PBM parameters, and the authors noted that there remains a need to identify optimal PBM parameters per cancer treatment modality.

Based on this evidence and on our experience, we propose the following regimen for the management of OM and mucositis affecting the oropharynx: wavelength of 633–685 or 780–830 nm; power output of between 10 and 150mW; *energy density* 2–3 J/cm<sup>2</sup>, and no more than 6 J/cm<sup>2</sup> on the tissue surface treated; administered two to three times a week up to daily; and using successive intraoral applications on single spots on the mucosa, rather than a scanning motion over the entire mucosal surface. The upper safety limit was set as a precaution since no clinical data defining a safe upper limit are currently available. *Emission type*, continuous or pulsed (<100 Hz) as low-frequency pulsed light may be superior to continuous wave light for wound healing or the prevention of injury. Extraorally administered PBM may be effective for the management of OM of the buccal mucosa, vestibule, and inner epithelial surfaces of the lips which could be applied in combination with an intraoral device.

## Dermatitis

Radiation dermatitis occurs in the majority of patients with locoregionally advanced HNC treated with RT.

The pathobiology of acute radiation dermatitis is complex and partially overlaps that of OM. Irradiation of the skin leads to direct tissue injury and inflammatory cell recruitment, involving damage to epidermal basal cells and connective tissue including endothelial cells and vascular components [19]. Radiation-induced generation of free radicals induces DNA injury and release of inflammatory cytokines [mainly interleukin (IL)-1 and IL-6] [20, 21]. This process leads to the development of erythema, edema, and possible ulceration. Late RT-induced changes involving skin are characterized by the loss of follicular structures, an increase in collagen and damage to elastic fibers in the dermis, and a fragile epidermal covering [22]. Transforming growth factor beta (TGF- $\beta$ ) is considered to play a central role in mediating RT-induced tissue fibrosis [23–25].

The severity of skin reactions is dependent on the total radiation dose, the dose per fraction, the overall treatment time, beam type and energy, the surface area of the skin exposed to radiation, the use of combined chemoradiotherapy with or without targeted therapies, and individual risk factors [20]. The severity of acute reactions has been shown to predict late effects. Radiation dermatitis impacts adversely on cosmesis and function and reduces QoL, especially in patients who develop secondarily infected dermatitis [19].

Patients with head and neck squamous cell carcinoma (HNSCC) treated with an epithelial growth factor receptor (EGFR) inhibitor may develop an acneiform skin rash in addition to radiation dermatitis [17, 22].

Based on the effects of PBM on the epidermis and dermis (reduced inflammation and improved wound healing), and on the shared similarities in pathobiology with OM, it seems

reasonable to assume that PBM may reduce the prevalence and/or severity of radiation dermatitis [26–28].

A study in pigs suggested that multiwavelength PBM ameliorated the development of late radiation damage to the skin [29]. DeLand et al. [30] reported that LED treatments immediately after intensity-modulated radiation therapy (IMRT) reduced the incidence of radiation dermatitis in patients with breast cancer. However, Fife et al. [31] were not able to reproduce these results, although unfortunately, they did not specify important parameters such as irradiation time and size of area treated.

A case series report described promising results for PBM treatment at a NIR wavelength (970 nm) in patients with EGFR inhibitor-induced facial rash [32].

## Dysphagia

Acute and chronic dysphagia and odynophagia are common in HNC patients, due to cancer following oropharyngeal/ laryngeal surgery and in those treated with RT or CRT [33, 34]. Dysphagia can be due to anatomical, mechanical, or neurological changes affecting any structure from the lips to the gastric cardia [35].

Dysphagia associated with RT or CRT has a complex pathogenesis, involving acute inflammation, edema, and fibrosis, with consequent neurological and muscular injury that may result in generalized weakness and a lack of muscle coordination while swallowing [34, 36, 37]. Excessive fibrosis results in a loss of elasticity that may contribute to chronic dysphagia [38, 39]. In addition, hyposalivation may contribute to dysphagia following RT [3]. Moreover, the duration of total parenteral nutrition (TPN) or tube feeding and resulting reduced swallowing may affect the ability to return to safe, normal oral intake, since inactivity will cause atrophy of the swallowing muscles [40, 41]. Dysphagia negatively affects QoL [3, 42] and may predispose to aspiration and life-threatening pulmonary complications [43, 44].

IMRT and more recently volumetric-modulated arc therapy (VMAT) have emerged as an effective technique to deliver the full radiation dose to the tumor and regions at risk while reducing exposure of surrounding healthy tissues. Eisbruch and coworkers [45] identified dysphagia/aspiration-related structures (DARS) as susceptible to damage during IMRT. In particular, damage to the tongue base, pharyngeal constrictors, the larynx, and the autonomic neural plexus was found to be crucial in the development of post-RT dysphagia. Studies confirmed that reducing the radiation dose to DARS decreases dysphagia risk [46–49]

In addition, preventive swallowing exercises in the pre-treatment setting had promising results on preserving (pharyngeal) swallowing function [48–50].

One study reported a lower incidence of severe OM and mucositis affecting the throat (contributing to acute dysphagia) when six predetermined oral sites were exposed to PBM prior to and during RT [51]. In this study, dysphagia was scored indirectly by assessing the need for TPN. Given the ability of PBM to prevent and ameliorate inflammation and pain associated with OM, and potential to control exuberant fibrosis [52], PBM delivered to the



DARS structures may have a potential role in the management of acute and chronic dysphagia. This requires further investigation.

### Hyposalivation and xerostomia

Another significant complication of RT to the head and neck region is hyposalivation, and its related complaint of xerostomia (subjective oral dryness). For all head and neck radiation regimens pooled, nearly all patients suffered from xerostomia as a result of RT [53].

Irradiation of the salivary glands results in loss of gland function, beginning early in the course of RT [54] and has been shown to induce apoptosis in parotid glands in a dose-dependent manner. This process is p53-dependent [55].

Saliva plays an important role in maintaining mucosal integrity, promoting oral wound healing, taste perception, formation of food bolus, initiation of food ingestion, swallowing, and speech [56]. Alterations in the oral microbiome, reduced oral clearance, changes in saliva composition (e.g., decreased buffer capacity, pH, immunoglobulin concentrations, defensins), and dietary changes may increase the risk for mucosal infections and rapidly progressing dental demineralization and caries [57]. A substantial decrease in salivary function has a significant impact on QoL and results in an increased burden of long-term dental care and nutrition [58–60].

There can be a modest improvement in xerostomia a few months after RT, suggesting that an adaptation or compensatory function of nonirradiated salivary glands or recovery of some of the function occurs. However, most patients have persisting oral dryness for the rest of their life, even when 3D conformal radiotherapy and IMRT is used. With IMRT preserving more of the major salivary glands, long-term oral dryness may be reduced, but a significant proportion of patients still experience xerostomia [61].

The literature on PBM for the management of hyposalivation is limited. In a study involving a variety of noncancer patients with xerostomia, PBM was applied daily: extraorally to the parotid and submandibular glands and intraorally on the sublingual glands. A gradual increase in the stimulated salivary flow was found after PBM compared to controls [62]. Similar results in noncancer patients were reported by Vidovič et al. [63]. Animal studies have shown an increase in the number of duct epithelial cell mitoses and stimulation to protein synthesis in submandibular glands following PBM [64, 65]. Similarly, a study reported the use of PBM to increase salivary flow rate and amylase activity in rat parotid glands [66]. These authors also performed a study in HNC patients and reported that PBM given concurrently with RT could prevent hyposalivation and xerostomia and had an impact on the composition of saliva [67]. Less severe xerostomia was also reported following PBM in HSCT recipients [68] and in patients treated with chemotherapy for solid tumors [69]. Increased salivary flow was observed in HNC patients treated with RT [70]. A recent study performed in HNC patients at least 6 months following conventional RT found no improvement of hyposalivation and xerostomia, likely due to irreversible acinar atrophy and fibrosis [71].

These results point to the potential use of PBM for prevention of hyposalivation/xerostomia; it may also show efficacy for the treatment of hyposalivation when there is residual gland function following current RT modalities.

### **Taste alterations**

Taste is one of the five senses and interacts with smell, touch, and other physiological cues to affect the wider perception of flavor. Disturbed taste (dysgeusia) is complex and includes difficulties with smell and touch resulting in reduced food interest and affecting appetite and QoL. Taste function is the perception derived when food molecules stimulate taste receptors of the tongue, soft palate, and the oropharyngeal region to perceive basic taste qualities (sweet, sour, salty, bitter, and umami), which can be measured via standardized methods [72].

The prevalence of dysgeusia is estimated to be 66.5 % following RT alone and 76.0 % after CRT; approximately 15 % of patients continued to experience dysgeusia after treatment [73]. Ohrn and colleagues reported that the severity of taste alterations assessed by patients was correlated with the cumulative RT dose [74].

The mechanisms of dysgeusia during cancer therapy are not well understood; however, it is believed that CT and RT cause dysgeusia by destroying rapidly dividing taste bud cells and olfactory receptor cells [73]. Direct neurologic toxicity may also be involved, as taste recovery lags epithelial recovery and may continue indefinitely [75]. Hyposalivation may also have a significant contribution. The presence of the anterior part of the tongue in the radiation field may be predictive of taste disturbances [76].

Altered taste significantly affects overall QoL and may lead to energy and nutrient deficiencies and related complications that may lead to weight loss [3, 73]. Management options to decrease the prevalence and severity of taste problems are inadequate [75].

A pilot study reported that PBM administered to taste buds may ameliorate neurologically mediated burning mouth syndrome symptoms including taste alterations [77], but to our knowledge, there are no published studies on PBM for the management of taste problems in cancer patients. Whether PBM has any efficacy in the management of dysgeusia in patients treated for HNC remains to be explored.

### **Trismus**

Trismus refers to reduced opening of the jaws that may be caused by spasm of the muscles of mastication, fibrosis in masticatory muscles, and temporomandibular joint disorders, which generally refers to mouth opening of less than 40 or less than 20 mm, whereas less restrictive classifications also have been used [78].

The prevalence of trismus is estimated to be 25 % following conventional RT, 5 % following IMRT, and 31 % for CRT [79]. Patients may have limitations in jaw opening associated with tumor invasion of the masticatory muscles or the temporomandibular joint, or may develop trismus following RT to these structures [78, 80]. Cumulative radiation doses above 60 Gy are more likely to cause trismus [81], while the inclusion of the lateral pterygoid muscles in



the high-dose fields appears to be the most decisive factor [82]. Trismus due to RT, typically develops 3–6 months post-RT associated with fibrosis and frequently becomes a lifelong problem [80, 83].

Studies have demonstrated that fibrosis is an important initial event in RT-induced trismus. Additionally, there may be scar tissue from surgery, nerve damage, or a combination of these factors [80]. Mandibular hypomobility ultimately results in muscle contraction and potentially temporomandibular joint dysfunction [79].

Trismus and orofacial pain interfering with function may have significant health implications including reduced nutritional intake, difficulty speaking, compromised oral health, and poor QoL [84]. Aside from avoiding RT to the masticatory structures, early interventions (e.g., mouth opening exercises) are indicated to prevent or minimize trismus [48, 85, 86].

Concerning muscle spasms following oral surgery, a reduction was found in several studies using PBM [87, 88]. To our knowledge, PBM to prevent or reduce the severity of RT-induced trismus in HNC patients has not been reported. The evidence for PBM to reduce fibrosis and promote muscle regeneration forms the main rationale for a potential clinical benefit and justifies further study.

### **Soft tissue necrosis and osteoradionecrosis**

Soft tissue and/or osteoradionecrosis (ORN) may occur as a consequence of RT. ORN is a process of radiation-induced vascular occlusion leading to loss of osteocytes and bone necrosis following RT [89]. The incidence of ORN has declined with proper pretreatment dental care and advances in RT; in conventional RT, mandibular ORN prevalence ranges from 5 to 15 %. More recently, in the era of IMRT, less than 5 % of patients are affected [60, 80, 90].

The pathogenesis of ORN is not completely understood. It has been proposed that ORN occurs following a radiation-induced fibroatrophic process, including free radical formation, endothelial dysfunction, inflammation, microvascular thrombosis, fibrosis and remodeling, and finally bone and tissue necrosis [91]. Common triggers of necrosis are inflammatory dental disease, trauma to soft tissue, and dental surgical procedures in sites of high-dose radiation exposure to bone. Dental surgery after RT is considered a critical risk factor for ORN, but ORN can also arise due to periodontal disease, trauma or spontaneously [92–94]. Prevention of ORN is mainly based on extractions of compromised teeth before RT and adequate dental care and prevention during and following cancer therapy [1, 89].

PBM has a biostimulatory effect on irradiated rat bone when applied before and during RT [95], and similar results were reported by El-Maghraby et al. [96]. In contrast, an in vivo study found that PBM was not able to reverse RT-induced bone damage [97]. To our knowledge, there are no clinical studies on the effects of PBM for RT-induced jaw osteonecrosis. However, multiple studies suggested a benefit from PBM in the management of medication-related osteonecrosis of the jaw (MRONJ) [98–101]. Vescovi et al. proposed a prophylactic protocol including PBM for reducing BRONJ incidence following tooth

extractions [102]. Luomanen et al. reported about a successful treatment of a patient with MRONJ using Nd:YAG laser [103]. A study in a rodent wound healing model found evidence that both laser and LED PBM were capable of stimulating angiogenesis in vivo [104].

The possible role of PBM in the management of RT-induced jaw osteonecrosis deserves further exploration.

### **Head and neck lymphedema**

A commonly neglected late effect in patients treated for HNC is secondary lymphedema [105], although this complication may be reduced with IMRT. Patients may develop lymphedema externally, on the face and neck, and/or internally involving the larynx and pharynx. External lymphedema may have a profound effect on appearance and body image [106], whereas internal lymphedema may impact breathing, contribute to dysphagia and trismus, and may affect speech [107].

In a single center study on 81 HNC patients, 75 % had lymphedema. Of those, 10 % had external, 39 % had internal, and 51 % had both types of lymphedema [107]. Individuals with pharyngeal carcinoma were at highest risk [108]. Lymphedema typically develops 2–6 months after the completion of RT and may resolve spontaneously in some patients, but not in all. Assessment and measurement of head and neck lymphedema remains challenging [109].

Lymphedema is initiated by disruption of lymphatic structures by surgery, RT or both, resulting in the accumulation of lymph fluid in the interstitial tissues. This leads to infiltration of inflammatory cells and, because of the lymphatic dysfunction, cytokines and chemokines remain in the tissue and recruit additional inflammatory cells from the circulation. This ongoing inflammatory response results in additional soft tissue damage and fibrosis, which further adversely affects lymphatic function [110].

PBM has been identified as a potential treatment for post-mastectomy lymphedema, as it stimulates lymphangiogenesis, enhances lymphatic motility, and reduces lymphostatic fibrosis [111]. Patients received additional benefits from PBM when used in conjunction with standard lymphedema treatment [112]. Systematic reviews found evidence suggesting that PBM reduced limb volume in patients with lymphedema following treatment for breast cancer [113–115]. It was concluded that future research should be performed comparing PBM with standard practices and to establish the duration of light application, number of treatment sessions, energy settings, power density, and dose. In addition, longer follow-up was considered necessary [114]. Lee and coworkers proposed that PBM may also have a role in the management of lymphedema associated with HNC [116].

### **Voice and speech alterations**

Voice and speech are important communication tools and form part of a person's identity and personality. Voice quality mainly depends on the movement and characteristics of the vocal cords, and speech on the resonance characteristics of the vocal tract. Speech is based on the volitional coordinated movements of the articulator structures and can be affected by

any alteration in muscle or tissue properties of these structures. Although voice and speech dysfunctions significantly affect QoL, these complications have received little attention and are likely underreported in efforts to preserve organ function after cancer therapy [117–119].

Currently, there is limited information on the prevalence of speech and voice dysfunction in advanced HNC patients treated with RT or CRT. Prospective studies are needed, including baseline measurements and standardized multidimensional assessment of functional aspects of voice and speech [118].

The etiology of voice and speech problems resembles that of dysphagia and may include neuromuscular weakness as a result of tumor invasion. Dependent on the dose tolerance of the critical organs involved, CRT-induced voice and/or speech dysfunction can result from mucositis of the soft palate, tongue and laryngeal soft tissues, edema, fibrosis, or atrophy of the vocal folds, pharyngeal and oral tissues, and altered saliva or hyposalivation [120–122].

New RT delivery techniques designed to spare these structures may prevent functional impairment.

A study using an animal model of reflux laryngitis (a condition including hoarseness, voice fatigue, globus, chronic cough, throat pain, and dysphagia) suggested that the anti-inflammatory effects of PBM may play in the management of this condition [123].

We are not aware of any studies on the effect of PBM on the quality of speech and voice in HNC patients. Since PBM may preserve function of the anatomical structures involved by its anti-inflammatory effects and may have indirect benefits by stimulating the salivary flow, future studies are warranted.

## Conclusion

Acute and chronic complications induced by RT and CRT in patients with HNC represent a significant clinical challenge [1]. There are similarities with respect to pathophysiology across different complications, and patients may suffer from multiple concurrent and interrelated problems [13]. There is anecdotal evidence suggesting that the inflammation associated with acute complications is a harbinger for chronic complications. This observation suggests that preventive approaches starting before, and in the early phases of treatment with RT and CRT, may not only reduce the risk for developing acute problems but may also have an impact on the risk for late complications.

PBM has shown effectiveness in the management of OM and elicits several potentially beneficial effects, including reduction of inflammation and pain, promotion of tissue repair, reduction of fibrosis, and protection and regeneration of nerves. Therefore, there is a clear motivation for studies on the application of PBM for the prevention and treatment of a broad range of acute and chronic complications associated with RT or CRT in HNC patients.

The purpose of this article is to serve as a basis for establishing a platform for facilitating future collaborations among clinicians and researchers, in order to create firm scientific evidence for the use of PBM in patients with HNC. PBM protocols should be administered

using parameters that are likely to affect the anatomic structures at risk. The parameters (including the wavelengths) we have proposed are largely based on evidence derived from studies using PBM for the management of OM (typically 633–685 or 780–830 nm). However, trials directed to other (non-head and neck) indications for the use of PBM suggest that a broader range of wavelengths (590–1064 nm) has efficacy for healing and for reducing inflammation and pain. Future investigations should be conducted to better define optimal PBM parameters for each of the complications of HNC treatment. LED specifics need to be carefully matched to PBM using lasers when considering LED arrays and using them clinically. In addition, the ideal timing and frequency of PBM administration should be determined, as well as how long PBM should be continued following the completion of cancer treatment. PBM parameters should be reported in detail (discussed in part 1) and validated outcome measures must be identified and employed to assess the effect of prophylaxis and therapy, from the time of diagnosis through active treatment and survival.

Despite the potential benefits and plausible safety of PBM for supportive care in HNC patients, vigilance remains warranted. While the reported results of in vitro studies of PBM on malignant cells vary, and clinical reports have shown little or no adverse reactions, there is a paucity of robust data regarding potential protection and promotion of tumor. Studies should be also directed to the potential beneficial effects of PBM by enhancing the efficacy of (C)RT or immunologic antitumor reactivity.

Investigations on the efficacy of PBM in the management of side effects of HNC treatment should be conducted. It is imperative that such studies include elucidating the effects of PBM on oncology treatment outcomes.

## References

1. Epstein JB, Thariat J, Bensadoun RJ, Barasch A, Murphy BA, Kolnick L, et al. Oral complications of cancer and cancer therapy: from cancer treatment to survivorship. *CA Cancer J Clin.* 2012; 62(6): 400–422.10.3322/caac.21157 [PubMed: 22972543]
2. Elting LS, Keefe DM, Sonis ST, Garden AS, Spijkervet FK, Barasch A, et al. Patient-reported measurements of oral mucositis in head and neck cancer patients treated with radiotherapy with or without chemotherapy: demonstration of increased frequency, severity, resistance to palliation, and impact on quality of life. *Cancer.* 2008; 113(10):2704–2713.10.1002/cncr.23898 [PubMed: 18973181]
3. Cooperstein E, Gilbert J, Epstein JB, Dietrich MS, Bond SM, Ridner SH, et al. Vanderbilt Head and Neck Symptom Survey version 2.0: report of the development and initial testing of a subscale for assessment of oral health. *Head Neck.* 2012; 34(6):797–804.10.1002/hed.21816 [PubMed: 22127786]
4. Hunter KU, Schipper M, Feng FY, Lyden T, Haxer M, Murdoch-Kinch CA, et al. Toxicities affecting quality of life after chemo-IMRT of oropharyngeal cancer: prospective study of patient-reported, observer-rated, and objective outcomes. *Int J Radiat Oncol Biol Phys.* 2013; 85(4):935–940.10.1016/j.ijrobp.2012.08.030 [PubMed: 23040224]
5. Verdonck-de Leeuw IM, Buffart LM, Heymans MW, Rietveld DH, Doornaert P, de Bree R, et al. The course of health-related quality of life in head and neck cancer patients treated with chemoradiation: a prospective cohort study. *Radiother Oncol: J Eur Soc Ther Radiol Oncol.* 2014; 110(3):422–428.10.1016/j.radonc.2014.01.002
6. Raber-Durlacher JE, Scully C. Oral cancer: comprehending the condition, causes, controversies, control and consequences.14. *Mucositis. DentUpdate.* 2012; 39(2):145–147.

7. Clarkson JE, Worthington HV, Furness S, McCabe M, Khalid T, Meyer S. Interventions for treating oral mucositis for patients with cancer receiving treatment. *Cochrane Database Syst Rev.* 2010; 8:CD001973.10.1002/14651858.CD001973.pub4 [PubMed: 20687070]
8. Worthington HV, Clarkson JE, Bryan G, Furness S, Glenny AM, Littlewood A, et al. Interventions for preventing oral mucositis for patients with cancer receiving treatment. *Cochrane Database Syst Rev.* 2011; 4:CD000978.10.1002/14651858.CD000978.pub5 [PubMed: 21491378]
9. Bjordal JM, Bensadoun RJ, Tuner J, Frigo L, Gjerde K, Lopes-Martins RA. A systematic review with meta-analysis of the effect of low-level laser therapy (LLLT) in cancer therapy-induced oral mucositis. *Support Care Cancer.* 2011; 19(8):1069–1077.10.1007/s00520-011-1202-0 [PubMed: 21660670]
10. Bensadoun RJ, Nair RG. Low-level laser therapy in the prevention and treatment of cancer therapy-induced mucositis: 2012 state of the art based on literature review and meta-analysis. *Curr Opin Oncol.* 2012; 24(4):363–370.10.1097/CCO.0b013e328352eaa3 [PubMed: 22450151]
11. Migliorati C, Hewson I, Lalla RV, Antunes HS, Estilo CL, Hodgson B, et al. Systematic review of laser and other light therapy for the management of oral mucositis in cancer patients. *Support Care Cancer.* 2013; 21(1):333–341.10.1007/s00520-012-1605-6 [PubMed: 23001179]
12. Oberoi S, Zamperlini-Netto G, Beyene J, Treister NS, Sung L. Effect of prophylactic low level laser therapy on oral mucositis: a systematic review and meta-analysis. *PLoS ONE.* 2014; 9(9):e107418.10.1371/journal.pone.0107418 [PubMed: 25198431]
13. Sonis ST. A biological approach to mucositis. *J Support Oncol.* 2004; 2(1):21–32. discussion 5–6. [PubMed: 15330370]
14. Russi EG, Raber-Durlacher JE, Sonis ST. Local and systemic pathogenesis and consequences of regimen-induced inflammatory responses in patients with head and neck cancer receiving chemoradiation. *Mediat Inflamm.* 2014; 2014:518261.10.1155/2014/518261
15. Al-Dasooqi N, Sonis ST, Bowen JM, Bateman E, Blijlevens N, Gibson RJ, et al. Emerging evidence on the pathobiology of mucositis. *Support Care Cancer.* 2013.10.1007/s00520-013-1900-x
16. Watters AL, Epstein JB, Agulnik M. Oral complications of targeted cancer therapies: a narrative literature review. *Oral Oncol.* 2011; 47(6):441–448.10.1016/j.oraloncology.2011.03.028 [PubMed: 21514211]
17. Lacouture ME, Anadkat MJ, Bensadoun RJ, Bryce J, Chan A, Epstein JB, et al. Clinical practice guidelines for the prevention and treatment of EGFR inhibitor-associated dermatologic toxicities. *Support Care Cancer.* 2011; 19(8):1079–1095.10.1007/s00520-011-1197-6 [PubMed: 21630130]
18. Lalla RV, Bowen J, Barasch A, Elting L, Epstein J, Keefe DM, et al. MASCC/ISOO clinical practice guidelines for the management of mucositis secondary to cancer therapy. *Cancer.* 2014; 120(10):1453–1461.10.1002/cncr.28592 [PubMed: 24615748]
19. Dorr W, Hendry JH. Consequential late effects in normal tissues. *Radiother Oncol.* 2001; 61(3): 223–231. [PubMed: 11730991]
20. Hymes SR, Strom EA, Fife C. Radiation dermatitis: clinical presentation, pathophysiology, and treatment 2006. *J Am Acad Dermatol.* 2006; 54(1):28–46.10.1016/j.jaad.2005.08.054 [PubMed: 16384753]
21. Kim JH, Kolozsvary AJ, Jenrow KA, Brown SL. Mechanisms of radiation-induced skin injury and implications for future clinical trials. *Int J Radiat Biol.* 2013; 89(5):311–318.10.3109/09553002.2013.765055 [PubMed: 23305180]
22. Bernier J, Bonner J, Vermorken JB, Bensadoun RJ, Dummer R, Giralt J, et al. Consensus guidelines for the management of radiation dermatitis and coexisting acne-like rash in patients receiving radiotherapy plus EGFR inhibitors for the treatment of squamous cell carcinoma of the head and neck. *Ann Oncol.* 2008; 19(1):142–149.10.1093/annonc/mdm400 [PubMed: 17785763]
23. Martin M, Lefaix J, Delanian S. TGF-beta1 and radiation fibrosis: a master switch and a specific therapeutic target? *Int J Radiat Oncol Biol Phys.* 2000; 47(2):277–290. [PubMed: 10802350]
24. Westbury CB, Yarnold JR. Radiation fibrosis—current clinical and therapeutic perspectives. *Clin Oncol (RCollRadiol).* 2012; 24(10):657–672.10.1016/j.clon.2012.04.001
25. Mancini ML, Sonis ST. Mechanisms of cellular fibrosis associated with cancer regimen-related toxicities. *Front Pharmacol.* 2014; 5:51.10.3389/fphar.2014.00051 [PubMed: 24734020]

26. Avci P, Gupta A, Sadasivam M, Vecchio D, Pam Z, Pam N, et al. Low-level laser (light) therapy (LLLT) in skin: stimulating, healing, restoring. *Semin Cutan Med Surg.* 2013; 32(1):41–52. [PubMed: 24049929]
27. Costa MM, Silva SB, Quinto AL, Pasquinelli PF, de Queiroz dos Santos V, de Cassia SG, et al. Phototherapy 660 nm for the prevention of radiodermatitis in breast cancer patients receiving radiation therapy: study protocol for a randomized controlled trial. *Trials.* 2014; 15:330.10.1186/1745-6215-15-330 [PubMed: 25141962]
28. Bensadoun RJ, Nair RG. Low-level laser therapy in the Management Of Mucositis And Dermatitis Induced by cancer therapy. *Photomed Laser Surg.* 2015; 33(10):487–491.10.1089/pho.2015.4022 [PubMed: 26447605]
29. Rezvani M, Robbins ME, Hopewell JW, Whitehouse EM. Modification of late dermal necrosis in the pig by treatment with multi-wavelength light. *British J Radiol.* 1993; 66(782):145–149.
30. DeLand MM, Weiss RA, McDaniel DH, Geronemus RG. Treatment of radiation-induced dermatitis with light-emitting diode (LED) photomodulation. *Lasers Surg Med.* 2007; 39(2):164–168.10.1002/lsm.20455 [PubMed: 17311276]
31. Fife D, Rayhan DJ, Behnam S, Ortiz A, Elkeeb L, Aquino L, et al. A randomized, controlled, double-blind study of light emitting diode photomodulation for the prevention of radiation dermatitis in patients with breast cancer. *Dermatol Surg: Off Publ Am Soc Dermatol Surg [et Al].* 2010; 36(12):1921–1927.10.1111/j.1524-4725.2010.01801.x
32. Gobbo M, Ottaviani G, Mustacchi G, Di Lenarda R, Biasotto M. Acneiform rash due to epidermal growth factor receptor inhibitors: high-level laser therapy as an innovative approach. *Lasers Med Sci.* 2012; 27(5):1085–1090.10.1007/s10103-011-1029-4 [PubMed: 22120470]
33. Raber-Durlacher JE, Brennan MT, Verdonck-de Leeuw IM, Gibson RJ, Eilers JG, Waltimo T, et al. Swallowing dysfunction in cancer patients. *Support Care in Cancer: Off J Multinatl Assoc Support Care Cancer.* 2012; 20(3):433–443.10.1007/s00520-011-1342-2
34. Russi EG, Corvo R, Merlotti A, Alterio D, Franco P, Pergolizzi S, et al. Swallowing dysfunction in head and neck cancer patients treated by radiotherapy: review and recommendations of the supportive task group of the Italian Association Of Radiation Oncology. *Cancer Treat Rev.* 2012; 38(8):1033–1049.10.1016/j.ctrv.2012.04.002 [PubMed: 22542950]
35. Leslie P, Carding PN, Wilson JA. Investigation and management of chronic dysphagia. *BMJ (Clin Res Ed).* 2003; 326(7386):433–436.10.1136/bmj.326.7386.433
36. Mittal BB, Pauloski BR, Haraf DJ, Pelzer HJ, Argiris A, Vokes EE, et al. Swallowing dysfunction—preventative and rehabilitation strategies in patients with head-and-neck cancers treated with surgery, radiotherapy, and chemotherapy: a critical review. *Int J Radiat Oncol Biol Phys.* 2003; 57(5):1219–1230. [PubMed: 14630255]
37. Langmore SE. Evaluation of oropharyngeal dysphagia: which diagnostic tool is Superior? *Curr Opin Otolaryngol Head Neck Surg.* 2003; 11(6):485–489. [PubMed: 14631184]
38. Murphy BA, Gilbert J. Dysphagia in head and neck cancer patients treated with radiation: assessment, sequelae, and rehabilitation. *Semin Radiat Oncol.* 2009; 19(1):35–42.10.1016/j.semradonc.2008.09.007 [PubMed: 19028344]
39. Murphy BA, Dietrich MS, Wells N, Dwyer K, Ridner SH, Silver HJ, et al. Reliability and validity of the Vanderbilt head and neck symptom survey: a tool to assess symptom burden in patients treated with chemoradiation. *Head Neck.* 2010; 32(1):26–37.10.1002/hed.21143 [PubMed: 19626644]
40. van der Molen L, van Rossum MA, Burkhead LM, Smeele LE, Rasch CR, Hilgers FJ. A randomized preventive rehabilitation trial in advanced head and neck cancer patients treated with chemoradiotherapy: feasibility, compliance, and short-term effects. *Dysphagia.* 2011; 26(2):155–170.10.1007/s00455-010-9288-y [PubMed: 20623305]
41. Ganzer H, Touger-Decker R, Parrott JS, Murphy BA, Epstein JB, Huhmann MB. Symptom burden in head and neck cancer: impact upon oral energy and protein intake. *Support Care Cancer.* 2013; 21(2):495–503.10.1007/s00520-012-1542-4 [PubMed: 22825457]
42. Langendijk JA, Doornaert P, Verdonck-de Leeuw IM, Leemans CR, Aaronson NK, Slotman BJ. Impact of late treatment-related toxicity on quality of life among patients with head and neck



- cancer treated with radiotherapy. *J Clin Oncol.* 2008; 26(22):3770–3776.10.1200/JCO.2007.14.6647 [PubMed: 18669465]
43. Nguyen NP, Frank C, Moltz CC, Vos P, Smith HJ, Bhamidipati PV, et al. Aspiration rate following chemoradiation for head and neck cancer: an underreported occurrence. *Radiother Oncol.* 2006; 80(3):302–306.10.1016/j.radonc.2006.07.031 [PubMed: 16890314]
  44. Nguyen NP, Moltz CC, Frank C, Millar C, Smith HJ, Dutta S, et al. Effectiveness of the cough reflex in patients with aspiration following radiation for head and neck cancer. *Lung.* 2007; 185(5): 243–248.10.1007/s00408-007-9016-z [PubMed: 17661135]
  45. Eisbruch A, Lyden T, Bradford CR, Dawson LA, Haxer MJ, Miller AE, et al. Objective assessment of swallowing dysfunction and aspiration after radiation concurrent with chemotherapy for head-and-neck cancer. *Int J Radiat Oncol Biol Phys.* 2002; 53(1):23–28. [PubMed: 12007937]
  46. Langendijk JA, Doornaert P, Rietveld DH, Verdonck-de Leeuw IM, Leemans CR, Slotman BJ. A predictive model for swallowing dysfunction after curative radiotherapy in head and neck cancer. *Radiother Oncol.* 2009; 90(2):189–195.10.1016/j.radonc.2008.12.017 [PubMed: 19167120]
  47. Roe JW, Carding PN, Dwivedi RC, Kazi RA, Rhys-Evans PH, Harrington KJ, et al. Swallowing outcomes following intensity modulated radiation therapy (IMRT) for head & neck cancer - a systematic review. *Oral Oncol.* 2010; 46(10):727–733.10.1016/j.oraloncology.2010.07.012 [PubMed: 20850370]
  48. van der Molen L, Heemsbergen WD, de JR, van Rossum MA, Smeele LE, Rasch CR, et al. Dysphagia and trismus after concomitant chemo-intensity-modulated radiation therapy (chemo-IMRT) in advanced head and neck cancer; dose-effect relationships for swallowing and mastication structures. *Radiother Oncol.* 2013; 106(3):364–369.10.1016/j.radonc.2013.03.005 [PubMed: 23540551]
  49. Kraaijenga SA, Oskam IM, van der Molen L, Hamming-Vrieze O, Hilgers FJ, van den Brekel MW. Evaluation of long term (10-years+) dysphagia and trismus in patients treated with concurrent chemoradiotherapy for advanced head and neck cancer. *Oral Oncol.* 2015; 51(8):787–794.10.1016/j.oraloncology.2015.05.003 [PubMed: 26027851]
  50. Kraaijenga SA, van der Molen L, van den Brekel MW, Hilgers FJ. Current assessment and treatment strategies of dysphagia in head and neck cancer patients: a systematic review of the 2012/13 literature. *Current Opinion Support Palliative Care.* 2014; 8(2):152–163.10.1097/spc.0000000000000050
  51. Gautam AP, Fernandes DJ, Vidyasagar MS, Maiya AG, Vadhiraja BM. Low level laser therapy for concurrent chemoradiotherapy induced oral mucositis in head and neck cancer patients - a triple blinded randomized controlled trial. *Radiother Oncol.* 2012; 104(3):349–354.10.1016/j.radonc.2012.06.011 [PubMed: 22884841]
  52. Lev-Tov H, Brody N, Siegel D, Jagdeo J. Inhibition of fibroblast proliferation in vitro using low-level infrared light-emitting diodes. *Dermatol Surg.* 2013; 39(3 Pt 1):422–425.10.1111/dsu.12087 [PubMed: 23279196]
  53. Jensen SB, Pedersen AM, Vissink A, Andersen E, Brown CG, Davies AN, et al. A systematic review of salivary gland hypofunction and xerostomia induced by cancer therapies: prevalence, severity and impact on quality of life. *Support Care Cancer.* 2010; 18(8):1039–1060.10.1007/s00520-010-0827-8 [PubMed: 20237805]
  54. Burlage FR, Coppes RP, Meertens H, Stokman MA, Vissink A. Parotid and submandibular/sublingual salivary flow during high dose radiotherapy. *Radiother Oncol.* 2001; 61(3):271–274. [PubMed: 11730996]
  55. Avila JL, Grundmann O, Burd R, Limesand KH. Radiation-induced salivary gland dysfunction results from p53-dependent apoptosis. *Int J Radiat Oncol Biol Phys.* 2009; 73(2):523–529.10.1016/j.ijrobp.2008.09.036 [PubMed: 19147016]
  56. Pedersen AM, Bardow A, Jensen SB, Nauntofte B. Saliva and gastrointestinal functions of taste, mastication, swallowing and digestion. *Oral Dis.* 2002; 8(3):117–129. [PubMed: 12108756]
  57. Vissink A, Mitchell JB, Baum BJ, Limesand KH, Jensen SB, Fox PC, et al. Clinical management of salivary gland hypofunction and xerostomia in head-and-neck cancer patients: successes and barriers. *Int J Radiat Oncol Biol Phys.* 2010; 78(4):983–991.10.1016/j.ijrobp.2010.06.052 [PubMed: 20970030]

58. Epstein JB, Robertson M, Emerton S, Phillips N, Stevenson-Moore P. Quality of life and oral function in patients treated with radiation therapy for head and neck cancer. *Head Neck*. 2001; 23(5):389–398.10.1002/hed.1049 [PubMed: 11295813]
59. Shiboski CH, Hodgson TA, Ship JA, Schiodt M. Management of salivary hypofunction during and after radiotherapy. *Oral Surg Oral Med Oral Pathol Oral Radiol Endod*. 2007; 103(Suppl):S66–S19.10.1016/j.tripleo.2006.11.013 [PubMed: 17379158]
60. Buglione M, Cavagnini R, Di Rosario F, Sottocornola L, Maddalo M, Vassalli L, et al. Oral toxicity management in head and neck cancer patients treated with chemotherapy and radiation: dental pathologies and osteoradionecrosis (part 1) literature review and consensus statement. *Critical Rev Oncology/Hematol*. 2016; 97:131–142.10.1016/j.critrevonc.2015.08.010
61. Vissink A, van Luijk P, Langendijk JA, Coppes RP. Current ideas to reduce or salvage radiation damage to salivary glands. *Oral Dis*. 2015; 21(1):e1–10.10.1111/odi.12222 [PubMed: 24581290]
62. Loncar B, Stipetic MM, Baricevic M, Risovic D. The effect of low-level laser therapy on salivary glands in patients with xerostomia. *Photomed Laser Surg*. 2011; 29(3):171–175.10.1089/pho.2010.2792 [PubMed: 21054200]
63. Vidovic JD, Lukac J, Cekic-Arambasin A, Vidovic A, Canjuga I, Sikora M, et al. Effects of low-level laser treatment on mouth dryness. *Coll Antropol*. 2010; 34(3):1039–1043. [PubMed: 20977100]
64. Plavnik LM, De Crosa ME, Malberti AI. Effect of low-power radiation (helium/neon) upon submandibular glands. *J Clin Laser Med Surg*. 2003; 21(4):219–225.10.1089/104454703768247792 [PubMed: 13678459]
65. Takeda Y. Irradiation effect of low-energy laser on rat submandibular salivary gland. *J Oral Pathol*. 1988; 17(2):91–94. [PubMed: 3134538]
66. Simoes A, Nicolau J, de Souza DN, Ferreira LS, de Paula EC, Apel C, et al. Effect of defocused infrared diode laser on salivary flow rate and some salivary parameters of rats. *Clin Oral Investig*. 2008; 12(1):25–30.10.1007/s00784-007-0135-y
67. Simoes A, De CL, de Souza DN, de Matos JA, Freitas PM, nicolau J. Laser phototherapy as topical prophylaxis against radiation-induced xerostomia. *Photomed Laser Surg*. 2010; 28(3):357–363.10.1089/pho.2009.2486 [PubMed: 19814701]
68. Cowen D, Tardieu C, Schubert M, Peterson D, Resbeut M, Faucher C, et al. Low energy helium-neon laser in the prevention of oral mucositis in patients undergoing bone marrow transplant: results of a double blind randomized trial. *Int J Radiat Oncol Biol Phys*. 1997; 38(4):697–703. [PubMed: 9240635]
69. Arbabi-Kalati F, Arbabi-Kalati F, Moridi T. Evaluation of the effect of low level laser on prevention of chemotherapy-induced mucositis. *Acta Medica Iranica*. 2013; 51(3):157–162. [PubMed: 23605599]
70. Oton-Leite AF, Elias LS, Morais MO, Pinezi JC, Leles CR, Silva MA, et al. Effect of low level laser therapy in the reduction of oral complications in patients with cancer of the head and neck submitted to radiotherapy. *Spec Care Dent: Off Publ Am Assoc Hosp Dent Acad Dent Handicap. Am Soc Geriatr Dent*. 2013; 33(6):294–300.10.1111/j.1754-4505.2012.00303.x
71. Saleh J, Figueiredo MA, Cherubini K, Braga-Filho A, Salum FG. Effect of low-level laser therapy on radiotherapy-induced hyposalivation and xerostomia: a pilot study. *Photomed Laser Surg*. 2014; 32(10):546–552.10.1089/pho.2014.3741 [PubMed: 25302460]
72. Boltong A, Aranda S, Keast R, Wynne R, Francis PA, Chirgwin J, et al. A prospective cohort study of the effects of adjuvant breast cancer chemotherapy on taste function, food liking, appetite and associated nutritional outcomes. *PLoS ONE*. 2014; 9(7):e103512.10.1371/journal.pone.0103512 [PubMed: 25078776]
73. Hovan AJ, Williams PM, Stevenson-Moore P, Wahlin YB, Ohrn KE, Elting LS, et al. A systematic review of dysgeusia induced by cancer therapies. *Support Care Cancer*. 2010; 18(8):1081–1087.10.1007/s00520-010-0902-1 [PubMed: 20495984]
74. Ohrn KE, Wahlin YB, Sjoden PO. Oral status during radiotherapy and chemotherapy: a descriptive study of patient experiences and the occurrence of oral complications. *Support Care Cancer*. 2001; 9(4):247–257. [PubMed: 11430420]



75. Epstein JB, Barasch A. Taste disorders in cancer patients: pathogenesis, and approach to assessment and management. *Oral Oncol.* 2010; 46(2):77–81.10.1016/j.oraloncology.2009.11.008 [PubMed: 20036797]
76. Yamashita H, Nakagawa K, Nakamura N, Abe K, Asakage T, Ohmoto M, et al. Relation between acute and late irradiation impairment of four basic tastes and irradiated tongue volume in patients with head-and-neck cancer. *Int J Radiat Oncol Biol Phys.* 2006; 66(5):1422–1429.10.1016/j.ijrobp.2006.08.037 [PubMed: 17084561]
77. Romeo U, Del VA, Capocci M, Maggiore C, Ripari M. The low level laser therapy in the management of neurological burning mouth syndrome. A pilot study. *Ann Stomatol (Roma).* 2010; 1(1):14–18. [PubMed: 22238700]
78. Dijkstra PU, Huisman PM, Roodenburg JL. Criteria for trismus in head and neck oncology. *Int J Oral Maxillofac Surg.* 2006; 35(4):337–342.10.1016/j.ijom.2005.08.001 [PubMed: 16280237]
79. Bensadoun RJ, Riesenbeck D, Lockhart PB, Elting LS, Spijkervet FK, Brennan MT. A systematic review of trismus induced by cancer therapies in head and neck cancer patients. *Support Care Cancer.* 2010; 18(8):1033–1038.10.1007/s00520-010-0847-4 [PubMed: 20213237]
80. Vissink A, Jansma J, Spijkervet FK, Burlage FR, Coppes RP. Oral sequelae of head and neck radiotherapy. *Crit Rev Oral Biol Med.* 2003; 14(3):199–212. [PubMed: 12799323]
81. Teguh DN, Levendag PC, Voet P, van der Est H, Noever I, De KW, et al. trismus in patients with oropharyngeal cancer: relationship with dose in structures of mastication apparatus. *Head Neck.* 2008; 30(5):622–630.10.1002/hed.20760 [PubMed: 18213726]
82. Goldstein M, Maxymiw WG, Cummings BJ, Wood RE. The effects of antitumor irradiation on mandibular opening and mobility: a prospective study of 58 patients. *Oral Surg Oral Med Oral Pathol Oral Radiol Endod.* 1999; 88(3):365–373. [PubMed: 10503870]
83. Wang CJ, Huang EY, Hsu HC, Chen HC, Fang FM, Hsiung CY. The degree and time-course assessment of radiation-induced trismus occurring after radiotherapy for nasopharyngeal cancer. *Laryngoscope.* 2005; 115(8):1458–1460.10.1097/01.mlg.0000171019.80351.46 [PubMed: 16094124]
84. Dijkstra PU, Kalk WW, Roodenburg JL. Trismus in head and neck oncology: a systematic review. *Oral Oncol.* 2004; 40(9):879–889.10.1016/j.oraloncology.2004.04.003 [PubMed: 15380165]
85. van der Molen L, van Rossum MA, Burkhead LM, Smeele LE, Hilgers FJ. Functional outcomes and rehabilitation strategies in patients treated with chemoradiotherapy for advanced head and neck cancer: a systematic review. *Eur Arch Otorhinolaryngol.* 2009; 266(6):889–900.10.1007/s00405-008-0817-3 [PubMed: 18825400]
86. Carnaby-Mann G, Crary MA, Schmalfuss I, Amdur R. “Pharyngocise”: randomized controlled trial of preventative exercises to maintain muscle structure and swallowing function during head-and-neck chemoradiotherapy. *Int J Radiat Oncol Biol Phys.* 2012; 83(1):210–219.10.1016/j.ijrobp.2011.06.1954 [PubMed: 22014959]
87. Carrillo JS, Calatayud J, Manso FJ, Barberia E, Martinez JM, Donado M. A randomized double-blind clinical trial on the effectiveness of helium-neon laser in the prevention of pain, swelling and trismus after removal of impacted third molars. *Int Dental J.* 1990; 40(1):31–36.
88. Aras MH, Gungormus M. Placebo-controlled randomized clinical trial of the effect two different low-level laser therapies (LLLT)–intraoral and extraoral–on trismus and facial swelling following surgical extraction of the lower third molar. *Lasers Med Sci.* 2010; 25(5):641–645.10.1007/s10103-009-0684-1 [PubMed: 19484402]
89. Chrcanovic BR, Reher P, Sousa AA, Harris M. Osteoradionecrosis of the jaws—a current overview—part 1: physiopathology and risk and predisposing factors. *Oral Maxillofac Surg.* 2010; 14(1):3–16.10.1007/s10006-009-0198-9 [PubMed: 20119841]
90. Epstein J, van der Meij E, McKenzie M, Wong F, Lepawsky M, Stevenson-Moore P. Postradiation osteonecrosis of the mandible: a long-term follow-up study. *Oral Surg Oral Med Oral Pathol Oral Radiol Endod.* 1997; 83(6):657–662. [PubMed: 9195618]
91. Delanian S, Lefaix JL. The radiation-induced fibroatrophic process: therapeutic perspective via the antioxidant pathway. *Radiother Oncol.* 2004; 73(2):119–131.10.1016/j.radonc.2004.08.021 [PubMed: 15542158]

92. Bagan JV, Jimenez Y, Hernandez S, Murillo J, Diaz JM, Poveda R, et al. Osteonecrosis of the jaws by intravenous bisphosphonates and osteoradionecrosis: a comparative study. *Med Oral Patol Oral Cir Bucal*. 2009; 14(12):e616–e6. e9. [PubMed: 19949369]
93. Madrid C, Abarca M, Bouferrache K. Osteoradionecrosis: an update. *Oral Oncol*. 2010; 46(6):471–474.10.1016/j.oraloncology.2010.03.017 [PubMed: 20457536]
94. Schuurhuis JM, Stokman MA, Witjes MJ, Dijkstra PU, Vissink A, Spijkervet FK. Evidence supporting pre-radiation elimination of oral foci of infection in head and neck cancer patients to prevent oral sequelae. A systematic review. *Oral Oncol*. 2015; 51(3):212–220.10.1016/j.oraloncology.2014.11.017 [PubMed: 25524386]
95. Da Cunha SS, Sarmiento V, Ramalho LM, De Almeida D, Veeck EB, Da Costa NP, et al. Effect of laser therapy on bone tissue submitted to radiotherapy: experimental study in rats. *Photomed Laser Surg*. 2007; 25(3):197–204.10.1089/pho.2007.2002 [PubMed: 17603861]
96. El-Maghraby EM, El-Rouby DH, Saafan AM. Assessment of the effect of low-energy diode laser irradiation on gamma irradiated rats' mandibles. *Arch Oral Biol*. 2013; 58(7):796–805.10.1016/j.archoralbio.2012.10.003 [PubMed: 23102551]
97. Batista JD, Zanetta-Barbosa D, Cardoso SV, Dechichi P, Rocha FS, Pagnoncelli RM. Effect of low-level laser therapy on repair of the bone compromised by radiotherapy. *Lasers Med Sci*. 2014; 29(6):1913–1918.10.1007/s10103-014-1602-8 [PubMed: 24913422]
98. Scoletta M, Arduino PG, Reggio L, Dalmasso P, Mozzati M. Effect of low-level laser irradiation on bisphosphonate-induced osteonecrosis of the jaws: preliminary results of a prospective study. *Photomed Laser Surg*. 2010; 28(2):179–184.10.1089/pho.2009.2501 [PubMed: 19795990]
99. Romeo U, Galanakis A, Marias C, Vecchio AD, Tenore G, Palaia G, et al. Observation of pain control in patients with bisphosphonate-induced osteonecrosis using low level laser therapy: preliminary results. *Photomed Laser Surg*. 2011; 29(7):447–452.10.1089/pho.2010.2835 [PubMed: 21235406]
100. Vescovi P, Merigo E, Meleti M, Manfredi M, Fornaini C, Nammour S. Surgical approach and laser applications in BRONJ osteoporotic and cancer patients. *J Osteoporos*. 2012; 2012:585434.10.1155/2012/585434 [PubMed: 22645701]
101. da Guarda MG, Paraguassu GM, Cerqueira NS, Cury PR, Farias JG, Ramalho LM. Laser GaAlAs (lambda860 nm) photobiomodulation for the treatment of bisphosphonate-induced osteonecrosis of the jaw. *Photomed Laser Surg*. 2012; 30(5):293–297.10.1089/pho.2011.3219 [PubMed: 22509722]
102. Vescovi P, Giovannacci I, Merigo E, Meleti M, Manfredi M, Fornaini C, et al. Tooth extractions in high-risk patients under bisphosphonate therapy and previously affected with osteonecrosis of the jaws: surgical protocol supported by low-level laser therapy. *J Craniofac Surg*. 2015; 26(3):696–699.10.1097/scs.0000000000001665
103. Luomanen M, Alaluusua S. Treatment of bisphosphonate-induced osteonecrosis of the jaws with Nd:YAG laser biostimulation. *Lasers Med Sci*. 2012; 27(1):251–255.10.1007/s10103-011-0929-7 [PubMed: 21597949]
104. de Sousa AP, Paraguassu GM, Silveira NT, de Cangussu SJMC, Dos Santos JN, et al. Laser and LED phototherapies on angiogenesis. *Lasers Med Sci*. 2013; 28(3):981–987.10.1007/s10103-012-1187-z [PubMed: 22923269]
105. Smith BG, Lewin JS. Lymphedema management in head and neck cancer. *Curr Opin Otolaryngol Head Neck Surg*. 2010; 18(3):153–158.10.1097/MOO.0b013e32833aac21 [PubMed: 20463478]
106. McGarvey AC, Osmotherly PG, Hoffman GR, Chiarelli PE. Lymphoedema following treatment for head and neck cancer: impact on patients, and beliefs of health professionals. *Eur J Cancer Care*. 2014; 23(3):317–327.10.1111/ecc.12134
107. Deng J, Ridner SH, Dietrich MS, Wells N, Wallston KA, Sinard RJ, et al. Prevalence of secondary lymphedema in patients with head and neck cancer. *J Pain Symptom Manage*. 2012; 43(2):244–252.10.1016/j.jpainsymman.2011.03.019 [PubMed: 21802897]
108. Deng J, Ridner SH, Dietrich MS, Wells N, Wallston KA, Sinard RJ, et al. Factors associated with external and internal lymphedema in patients with head-and-neck cancer. *Int J Radiat Oncol Biol Phys*. 2012; 84(3):e319–ee28.10.1016/j.ijrobp.2012.04.013 [PubMed: 22652102]




109. Deng J, Ridner SH, Aulino JM, Murphy BA. Assessment and measurement of head and neck lymphedema: state-of-the-science and future directions. *Oral Oncol.* 2015; 51(5):431–437.10.1016/j.oraloncology.2015.01.005 [PubMed: 25703799]
110. Deng J, Ridner SH, Murphy BA. Lymphedema in patients with head and neck cancer. *Oncol Nurs Forum.* 2011; 38(1):E1–E10.10.1188/11.ONFE.E1-E10 [PubMed: 21186146]
111. Lau RW, Cheing GL. Managing postmastectomy lymphedema with low-level laser therapy. *Photomed Laser Surg.* 2009; 27(5):763–769.10.1089/pho.2008.2330 [PubMed: 19878027]
112. Dirican A, Andacoglu O, Johnson R, McGuire K, Mager L, Soran A. The short-term effects of low-level laser therapy in the management of breast-cancer-related lymphedema. *Support Care Cancer: Off J Multinatl Assoc Support Care Cancer.* 2011; 19(5):685–690.10.1007/s00520-010-0888-8
113. Omar MT, Shaheen AA, Zafar H. A systematic review of the effect of low-level laser therapy in the management of breast cancer-related lymphedema. *Support Care Cancer.* 2012; 20(11):2977–2984.10.1007/s00520-012-1546-0 [PubMed: 22875413]
114. MTEL, JGEL, de Andrade MF, Bergmann A. Low-level laser therapy in secondary lymphedema after breast cancer: systematic review. *Lasers Med Sci.* 2012.10.1007/s10103-012-1240-y
115. Smoot B, Chiavola-Larson L, Lee J, Manibusan H, Allen DD. Effect of low-level laser therapy on pain and swelling in women with breast cancer-related lymphedema: a systematic review and meta-analysis. *J Cancer Survivorship: Res Practice.* 2015; 9(2):287–304.10.1007/s11764-014-0411-1
116. Wigg J, Lee N. Redefining essential care in lymphoedema. *British J Community Nurs.* 2014; S20(s2):s4–s7.
117. Dwivedi RC, Kazi RA, Agrawal N, Nutting CM, Clarke PM, Kerawala CJ, et al. Evaluation of speech outcomes following treatment of oral and oropharyngeal cancers. *Cancer Treat Rev.* 2009; 35(5):417–424.10.1016/j.ctrv.2009.04.013 [PubMed: 19481871]
118. Jacobi I, van der Molen L, Huiskens H, van Rossum MA, Hilgers FJ. Voice and speech outcomes of chemoradiation for advanced head and neck cancer: a systematic review. *Eur Arch Otorhinolaryngol.* 2010; 267(10):1495–1505.10.1007/s00405-010-1316-x [PubMed: 20589505]
119. van der Molen L, van Rossum MA, Jacobi I, van Son RJ, Smeele LE, Rasch CR, et al. Pre- and posttreatment voice and speech outcomes in patients with advanced head and neck cancer treated with chemoradiotherapy: expert listeners' and patient's perception. *J Voice.* 2012; 26(5):664–633.10.1016/j.jvoice.2011.08.016 [PubMed: 22209059]
120. Meleca RJ, Dworkin JP, Kewson DT, Stachler RJ, Hill SL. Functional outcomes following nonsurgical treatment for advanced-stage laryngeal carcinoma. *Laryngoscope.* 2003; 113(4):720–728.10.1097/00005537-200304000-00025 [PubMed: 12671435]
121. Johns MM, Kolachala V, Berg E, Muller S, Creighton FX, Branski RC. Radiation fibrosis of the vocal fold: from man to mouse. *Laryngoscope.* 2012; 122(Suppl 5):S107–SS25.10.1002/lary.23735 [PubMed: 23242839]
122. Jacobi I, Navran A, van der Molen L, Heemsbergen WD, Hilgers FJ, van den Brekel MW. Radiation dose to the tongue and velopharynx predicts acoustic-articulatory changes after chemo-IMRT treatment for advanced head and neck cancer. *Eur Arch oto-rhino-Laryngol: Off J Eur Fed Oto-Rhino-Laryngol Soc (EUFOS): Affiliated Ger Soc Oto-Rhino-Laryngol - Head Neck Surg.* 2015.10.1007/s00405-015-3526-8
123. Marinho RR, Matos RM, Santos JS, Ribeiro MA, Ribeiro RA, Lima RC Jr, et al. Potential anti-inflammatory effect of low-level laser therapy on the experimental reflux laryngitis: a preliminary study. *Lasers Med Sci.* 2014; 29(1):239–243.10.1007/s10103-013-1323-4 [PubMed: 23613090]


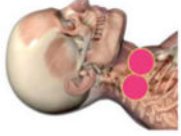
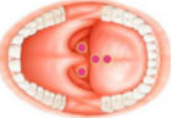


**Table 1** Suggested photobiomodulation regimens for prevention and/or treatment of cancer therapy-induced morbidity in head and neck cancer patients

Complication	Treatment protocol**	Treatment area	PBM Device Characteristics and application	Therapeutic PBM Dose	Optional target tissues
<b>Oral Mucositis</b>	<p><i>Prophylactic:</i> <i>Chemotherapy:</i> Protocols vary. Start PBM treatment at first day of CT or prior to therapy and continue during all courses of chemotherapy</p> <p><i>Radiotherapy:</i> start PBM treatment the first day of RT or prior to RT and continue during all days of RT (no requirement regarding the timing of PBM sessions, before of after RT session)</p> <p><i>Therapeutic:</i> Continue treatment at least 3 times a week until symptoms improve Daily treatment is recommended in case of severe mucositis</p>		<p><i>Extra-oral:</i> Infrared (IR) LED cluster or Mixed Red and IR LED cluster 20mW/cm<sup>2</sup> – 80mW/cm<sup>2</sup></p> <p><i>Intra-oral:</i> 630 – 830nm 20mW – 80mW</p>	<p><i>Extra-oral:</i> 3 J/cm<sup>2</sup> IR LED cluster</p> <p><i>Intra-oral:</i> <i>Prophylactic:</i> 2 J per point <i>Therapeutic:</i> 4 J per point until the whole area involved is covered (2 J for prophylactic use)</p>	<p><i>Extra-oral:</i> Lips, cutaneous surface corresponding to the buccal mucosae, bilateral cervical lymphatic chain*</p> <p><i>Intra-oral:</i> <i>Prophylactic:</i> treat each of the at risk mucosal surfaces.* <i>Therapeutic:</i> sites vary, depending upon the site of mucositis</p>
<b>Radiation dermatitis</b>	<p><i>Prophylactic:</i> Start daily PBM treatment at the initiation of RT, or with a grade 1 radiation dermatitis</p> <p><i>Therapeutic:</i> Continue treatment at least 3 times a week until symptoms improve</p>		<p><i>Extra-oral:</i> Red laser diodes cluster, 630–680 nm, 20–150 mW/cm<sup>2</sup> or Mixed Red and IR LED cluster 20mW/cm<sup>2</sup> – 80mW/cm<sup>2</sup></p>	<p><i>Extra-oral:</i> <i>Prophylactic:</i> 2 J/cm<sup>2</sup> for laser diodes panel, 3 J/cm<sup>2</sup> for extra oral LED Cluster <i>Therapeutic:</i> At least 4 J/cm<sup>2</sup></p>	<p><i>Extra-oral:</i> Cutaneous surfaces on the radiation field where dermatitis is anticipated (often erythematous after RT)</p>
<b>Dysphagia</b>	<p><i>Prophylactic:</i> <i>Radiotherapy:</i> start treatment the first day of radiotherapy and continue all days of radiation (no requirement regarding the timing of laser sessions, before of after radiation session)</p> <p><i>Therapeutic:</i> Continue treatment at least 3 times a week until symptoms improve</p>	<p><i>Extra-oral:</i> Lateral and ventral pharynx and larynx</p> <p><i>Intraoral:</i> Soft palate, oropharynx</p>	<p><i>Extra-oral:</i> IR laser diodes or LED cluster 750– 830 nm 20mW/cm<sup>2</sup> – 80mW/cm<sup>2</sup></p> <p><i>Intra-oral:</i> 630 – 680nm 20mW – 150mW</p>	<p><i>Extra-oral:</i> <i>Prophylactic:</i> 3 J/cm<sup>2</sup> laser diodes or LED cluster <i>Intra-oral:</i> <i>Prophylactic:</i> 3 J per point</p>	<p><i>Extra-oral:</i> Midline neck and lateral neck anterior to sternocleidomastoid muscle <i>Intra-oral:</i> Bilaterally, 4 points to soft palate and onto oropharynx</p>



Complication	Treatment protocol**	Treatment area	PBM Device Characteristics and application	Therapeutic PBM Dose	Optional target tissues
<b>Hyposalivation and xerostomia</b>	<i>Prophylactic:</i> <i>Radiotherapy:</i> start PBM treatment the first day of RT and continue daily with radiation (no requirement regarding the timing of PBM sessions, before of after RT session)		<i>Extra-oral:</i> IR laser diodes or LED cluster 750–830 nm 20mW/cm <sup>2</sup> – 80mW/cm <sup>2</sup> <i>Intra-oral:</i> 630 – 680nm 20mW – 150mW	<i>Extra-oral:</i> Prophylactic: 3 J/cm <sup>2</sup> laser diodes or LED cluster <i>Intra-oral:</i> Prophylactic: 3 J/cm <sup>2</sup> per point	<i>Extra-oral:</i> Major salivary glands, bilaterally (parotid, sublingual and submandibular)* <i>Intra-oral:</i> Total of 6 points (3 each side) targeting major salivary glands and minor salivary glands (on vestibular side, in the rear of salivary ducts)
<b>Dysgeusia</b>	<i>Therapeutic:</i> Continue treatment from the day the patient complains of taste alterations, at least 2 or 3 times a week until symptoms improve**		<i>Intra-oral:</i> 630 – 680nm 20mW – 150mW	<i>Intra-oral:</i> Dorsal and lateral tongue at 3 J/cm <sup>2</sup>	<i>Intra-oral:</i> A total of 10 points on the dorsum of the tongue
<b>Trismus</b>	<i>Prophylactic:</i> <i>Radiotherapy:</i> Apply PBM on pterygoid/TMJ region, at least 3 times a week, when high dose RT is given in that region (oropharyngeal and nasopharyngeal carcinoma for example). <i>Therapeutic:</i> Continue treatment from the day of diagnosis at least 2 or 3 times a week		<i>Extra-oral:</i> IR laser diodes or LED cluster 750–830 nm 20mW/cm <sup>2</sup> – 80mW/cm <sup>2</sup> <i>Intra-oral:</i> 630 – 680nm 20mW – 200mW	<i>Extra-oral:</i> 3–6 J/cm <sup>2</sup> laser diodes or LED cluster <i>Intra-oral:</i> 3 J per point	<i>Extra-oral:</i> Bilaterally over the temporalis muscle, TMJ, masseter muscle, buccinator muscle * <i>Intra-oral:</i> Bilaterally, point over the region of pterygoids/pterygomandibular raphae (may be difficult clinically) and other muscles of mastication *

Complication	Treatment protocol**	Treatment area	PBM Device Characteristics and application	Therapeutic PBM Dose	Optional target tissues
<b>Osteonecrosis</b>	<p><i>Therapeutic:</i> Continue treatment at least 2 or 3 times a week until symptoms improve Daily treatment is recommended Combination with other medical/surgical treatment approaches may be needed.</p>		<p><i>Extra-oral:</i> IR laser diodes or LED cluster 750–830 nm 20mW/cm<sup>2</sup> – 80mW/cm<sup>2</sup> <i>Intra-oral:</i> 630 – 680nm 20mW – 200mW</p>	<p><i>Extra-oral:</i> 6 J/cm<sup>2</sup> laser diodes or LED cluster <i>Intra-oral:</i> 6 J per point</p>	<p><i>Intra-oral:</i> 5 or more points (1 cm apart) along lingual and buccal aspects of maxilla and / or mandible depending on site and size of region affected *</p>
<b>Head and neck lymphedema</b>	<p><i>Therapeutic:</i> Continue treatment at least 2 or 3 times a week until symptoms improve</p>		<p><i>Extra-oral:</i> IR laser diodes or LED cluster 750– 830 nm 20mW/cm<sup>2</sup> – 80mW/cm<sup>2</sup></p>	<p><i>Extra-oral:</i> 3 J/cm<sup>2</sup> laser diodes or LED cluster</p>	<p><i>Extra-oral:</i> Treat edematous area over the neck or surgical site if any, also targeting regional lymphatic chain*</p>
<b>Voice/speech alterations (due to local inflammation)</b>	<p><i>Therapeutic:</i> Continue treatment from the day patient complains of difficulty speaking, at least 2 or 3 times a week even if symptoms are not improving dramatically.**</p>		<p><i>Intra-oral:</i> 780nm – 830nm 50mW – 200mW</p>	<p><i>Intra-oral:</i> 3 J/cm<sup>2</sup> per point <i>Extra-oral:</i> on larynx area, wavelength 750–830 nm IR laser diodes or LED cluster 20mW/cm<sup>2</sup> – 80mW/cm<sup>2</sup></p>	<p><i>Intra-oral:</i> Towards the anterior oropharynx over the dorsum of tongue (avoid gag reflex, do not touch any soft tissues including dorsal tongue). Patient may gently close the mouth during the procedure to reduce gag reflex</p>

These protocols are based on evidence derived from the literature (mainly derived from mucositis studies) and expert opinion and are intended to provide clinical guidance and to serve as a starting point for research. LED cluster probe dose has been expressed in J/cm<sup>2</sup>, and single point laser dose has been expressed in joules per point. For LED cluster probes, treatment time (s) = dose (J/cm<sup>2</sup>) / power density (W/cm<sup>2</sup>). For single-point laser probes, treatment time (s) = dose (J) / laser power (W)