

# Anatomy and Physiology of Feeding and Swallowing: Normal and Abnormal

Koichiro Matsuo, DDS, PhD<sup>a,b</sup>,  
Jeffrey B. Palmer, MD<sup>a,c,d,e,\*</sup>

<sup>a</sup>*Department of Physical Medicine and Rehabilitation, Johns Hopkins University,  
Phipps 160 600 North Wolfe Street, Baltimore, MD 21287, USA*

<sup>b</sup>*Department of Special Care Dentistry, Matsumoto Dental University,  
1780 Hirooka Gohara, Nagano, Japan, 399-0781*

<sup>c</sup>*Johns Hopkins Hospital, Phipps 160, 600 North Wolfe Street, Baltimore, MD 21287, USA*

<sup>d</sup>*Department of Otolaryngology–Head and Neck Surgery, Johns Hopkins University  
School of Medicine, Baltimore, MD, USA*

<sup>e</sup>*Functional Anatomy and Evolution, Johns Hopkins University School of Medicine,  
Baltimore, MD, USA*

## Anatomy

### *Anatomy of structures*

Understanding the normal physiology and pathophysiology of eating and swallowing is fundamental to evaluating and treating disorders of eating and swallowing and to developing dysphagia rehabilitation programs. Eating and swallowing are complex behaviors that include volitional and reflexive activities involving more than 30 nerves and muscles [1].

Fig. 1 shows the anatomy of the oral cavity, pharynx, and larynx; Table 1 lists the innervation of the major muscles related to swallowing. The tongue has oral and pharyngeal surfaces. The oral cavity is separated from the pharynx by the faucial pillars. The pharynx has a layer of constrictor muscles that originate on the cranium and hyoid bone and the thyroid cartilage anteriorly, and insert on a posterior median raphe. The submental muscles originate on the mandible and attach to the hyoid bone and tongue. The cricopharyngeus muscle is attached to the sides of the cricoid cartilage anteriorly and closes the upper esophageal sphincter (UES) by compressing it

---

\* Corresponding author. Department of Physical Medicine and Rehabilitation, Johns Hopkins University, Phipps 160, 600 North Wolfe Street, Baltimore, MD 21287.

E-mail address: [jpalm@jhmi.edu](mailto:jpalm@jhmi.edu) (J.B. Palmer).

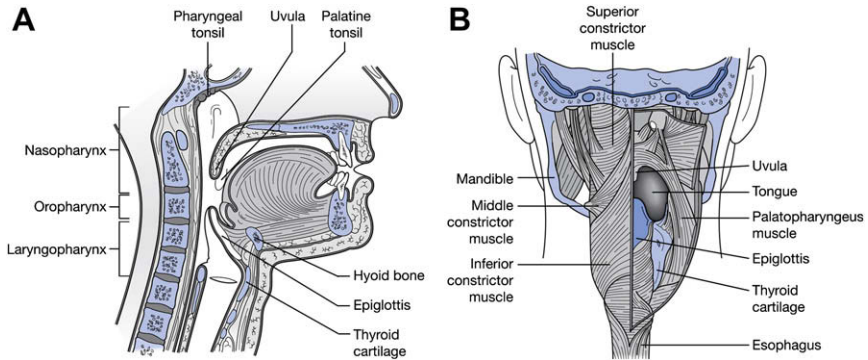


Fig. 1. Anatomy of the oral cavity and pharynx in the lateral (*A*) and posterior view (*B*). (From Moses K, Banks JC, Nava PB, et al. Atlas of clinical gross anatomy. Philadelphia: Elsevier; 2005; with permission.)

against the back of the cricoid cartilage. The epiglottis originates in the larynx and is angled upward and backward. It is attached to the hyoid bone anteriorly. The space between the pharyngeal surface of the tongue and the epiglottis is called the valleculae. The larynx includes the true and false vocal folds and the laryngeal surface of the epiglottis. The laryngeal

Table 1  
Innervation of major muscles related to swallowing

Cranial nerves	Muscles
Trigeminal nerve (V)	Masticatory muscles Mylohyoid Tensor veli palatini
Facial nerve (VII)	Anterior belly of digastrics Facial muscle Stylohyoid Posterior belly of digastrics
Glossopharyngeal nerve (IX)	Stylopharyngeus
Vagus nerve (X)	Levator veli palatine Palatopharyngeus Salpingopharyngeus Intrinsic laryngeal muscles Cricopharyngeus Pharyngeal constrictors
Hypoglossal nerve (XII)	Intrinsic tongue muscles Hyoglossus Geniohyoid Genioglossus Styloglossus Thyrohyoid

From Palmer JB, Monahan DM, Matsuo K. Rehabilitation of patients with swallowing disorders. In: Braddom R, editor. Physical medicine and rehabilitation. Philadelphia: Elsevier; 2006. p. 6; with permission.

aditus (upper end of the larynx) opens into the lower portion of the pharynx. Lateral to the larynx are two spaces in the pharynx called the pyriform recesses.

### *Development of anatomy*

The anatomy of the head and neck in infants is different from that in adults. In the infant, teeth are not erupted, the hard palate is flatter, and the larynx and hyoid bone are higher in the neck to the oral cavity. The epiglottis touches the back of the soft palate so that the larynx is open to the nasopharynx, but this airway is separated from the oral cavity by a soft tissue barrier (Fig. 2). The anatomy of the pharynx in humans changes with development. As the neck gets longer, the larynx descends to a position lower in the neck. The contact of the soft palate and epiglottis is lost, and the pharynx becomes longer vertically. This change in human development contributes to the development of speech, but because the pharynx becomes part of the food passageway and the airway (see Fig. 2), humans are vulnerable for aspiration.

### **Physiology**

Two paradigmatic models are commonly used to describe the physiology of normal eating and swallowing: the four-stage model for drinking and swallowing liquid and the process model for eating and swallowing solid

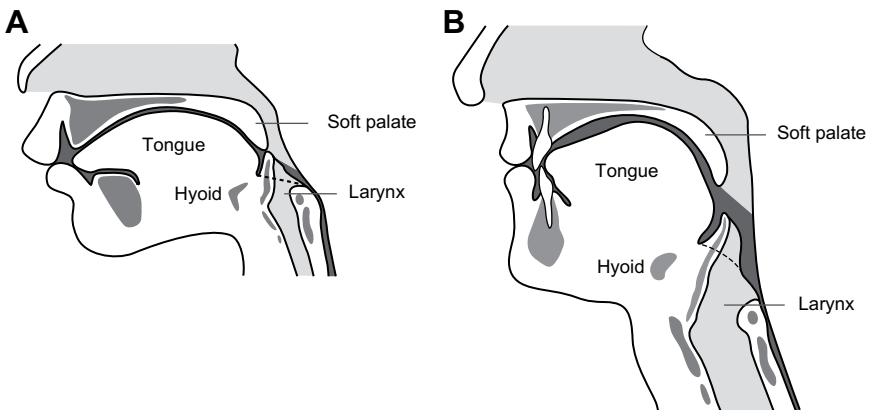


Fig. 2. Sagittal section of the head and neck in an infant (A) and an adult (B). The food passageway and the airway are shaded in dark gray and light gray, respectively. (A) In an infant, the oral cavity is smaller and the tongue and palate are flatter. The epiglottis is almost attached to the soft palate. The airway and food passageway are separated except when swallowing. (B) In an adult, the larynx is lower in the neck, and the food passageway and airway cross in the pharynx.

food. The normal swallow in humans was originally described using a three-stage sequential model whereby the swallowing process was divided into oral, pharyngeal, and esophageal stages according to the location of the bolus [2,3]. The oral stage was later subdivided into the oral-preparatory and oral-propulsive stages, thus establishing the four-stage model. Studies based on the four-stage model adequately describe the biomechanics and bolus movement during command swallows of liquids; however, this model cannot represent the bolus movement and the process of eating of solid food. Therefore, the process model of feeding was established to describe the mechanism of eating and swallowing solid food [4,5].

#### *Oral-preparatory stage*

After liquid is taken into the mouth from a cup or through a straw, the liquid bolus is held in the anterior part of the floor of the mouth or on the tongue surface against the hard palate surrounded by the upper dental arch (upper teeth). The oral cavity is sealed posteriorly by the contact between the soft palate and the tongue to prevent the liquid bolus from leaking into the oropharynx before the swallow. There may be leakage of liquid into the pharynx when the seal is imperfect, and this leakage increases with aging.

#### *Oral-propulsive stage*

During the oral-propulsive stage, the tongue tip rises, touching the alveolar ridge of the hard palate just behind the upper teeth, while the posterior tongue drops to open the back of the oral cavity. The tongue surface moves upward, gradually expanding the area of tongue–palate contact from anterior to posterior, squeezing the liquid bolus back along the palate and into the pharynx. When drinking liquids, the pharyngeal stage normally begins during oral propulsion.

#### *Oral stage in eating solid food (process model of feeding)*

The four-stage sequential model has limited utility for describing the process of normal eating in humans, especially that of food transport and bolus formation in the oropharynx [4–6]. When healthy subjects eat solid food, triturated (chewed and moistened) food commonly passes through the fauces for bolus formation in the oropharynx (including the valleculae) several seconds before the pharyngeal stage of a swallow. Additional portions of food can pass into the oropharynx and accumulate there while food remains in the oral cavity and chewing continues. This phenomenon is not consistent with the four-stage model because of the overlap among the oral-preparatory, oral-propulsive, and pharyngeal stages; the observable events during feeding on solid food are better described with the process model of feeding, which has its origin in studies of mammalian feeding [7] and was later adapted to feeding in humans [4].

### Stage I transport

When food is ingested into the mouth, the tongue carries the food to the postcanine region and rotates laterally, placing the food onto the occlusal surface of lower teeth for food processing.

### Food processing

Food processing immediately follows stage I transport. During food processing, food particles are reduced in size by mastication and are softened by salivation until the food consistency is optimal for swallowing. Chewing continues until all of the food is prepared for swallowing. Cyclic movement of the jaw in processing is tightly coordinated with the movements of the tongue, cheek, soft palate, and hyoid bone (Fig. 3).

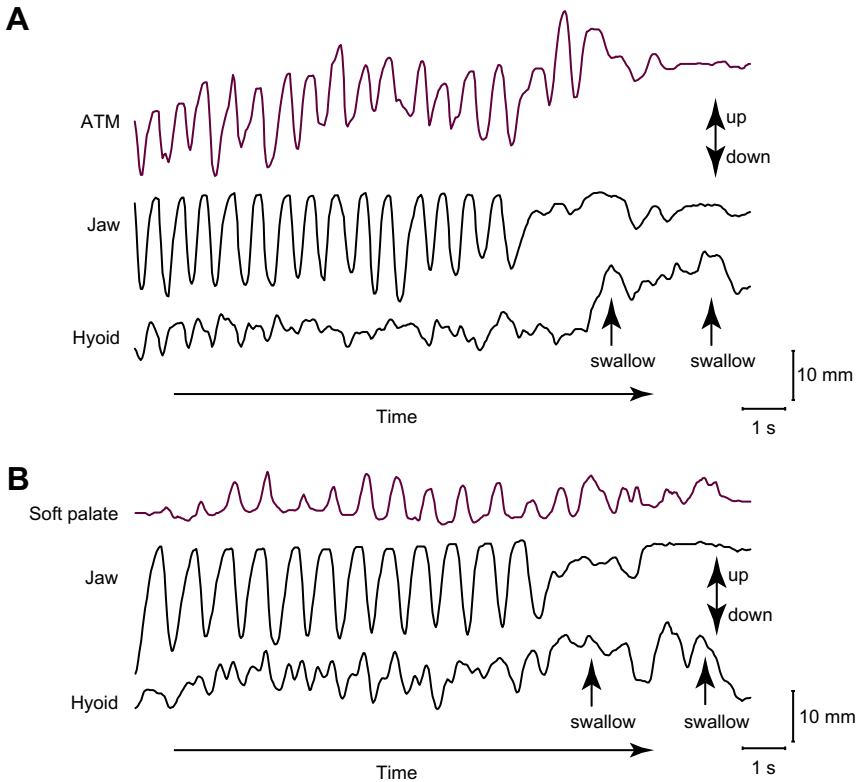


Fig. 3. Movements of (A) the anterior tongue marker (ATM), lower jaw, and hyoid bone, and (B) the soft palate, lower jaw, and hyoid bone over time, showing the vertical positions in a complete feeding sequence. Movement toward the top of the figure is upward. Positions of the structures are plotted relative to the upper jaw over time. Rhythmic movement of the tongue and soft palate is temporally linked to cyclic jaw movement. The hyoid also moves rhythmically; the amplitude of hyoid motion is greater in swallowing than in processing cycles.

During drinking of liquid, the posterior oral cavity is sealed by tongue–palate contact during the oral-preparatory stage when the bolus is held in the oral cavity. In contrast, during food processing, the tongue and soft palate move cyclically in association with jaw movement, permitting open communication between the oral cavity and pharynx [5,8]. Therefore, there is no sealing of the posterior oral cavity during eating. Movements of the jaw and tongue pump air into the nasal cavity through the pharynx, delivering the food's aroma to chemoreceptors in the nose [9–11].

Cyclic tongue movement during processing is coordinated with jaw movement [12]. Tongue movements during processing are large in the anteroposterior and vertical dimensions; jaw movements are similarly large in the vertical dimension (see Fig. 3A). During jaw opening, the tongue moves forward and downward, reaching its most anterior point in mid to late jaw opening. It then reverses direction and moves backward in late jaw opening, preventing us from biting our tongues when we eat. The tongue also moves mediolaterally and rotates on its long (anteroposterior) axis during chewing [13]. These motions are coordinated with cheek movement to keep food on the occlusal surfaces of the lower teeth. The hyoid bone also moves constantly during feeding, but its motion is more variable than jaw or tongue movements (see Fig 3A and B). The hyoid has mechanical connections to the cranial base, mandible, sternum, and thyroid cartilage by way of the suprahyoid and infrahyoid muscles. With those muscle connections, the hyoid plays an important role in controlling the movements of the jaw and tongue.

### *Stage II transport*

When a portion of the food is suitable for swallowing, it is placed on the tongue surface and propelled back through the fauces to the oropharynx (Fig. 4). The basic mechanism of stage II transport is the same as described for the oral-propulsive stage with a liquid bolus. The anterior tongue surface first contacts the hard palate just behind the upper incisors. The area of tongue–palate contact gradually expands backward, squeezing the triturated food back along the palate to the oropharynx. Stage II transport is primarily driven by the tongue and does not require gravity [14,15]. Stage II transport can be interposed into food processing cycles. The transported food accumulates on the pharyngeal surface of the tongue and in the valleculae. Chewing continues when food remains in the oral cavity, and the bolus in the oropharynx is enlarged by subsequent stage II transport cycles. The duration of bolus aggregation in the oropharynx ranges from a fraction of a second to about 10 seconds in normal individuals eating solid food [5].

### *Pharyngeal stage*

Pharyngeal swallow is a rapid sequential activity, occurring within a second. It has two crucial biologic features: (1) food passage—propelling

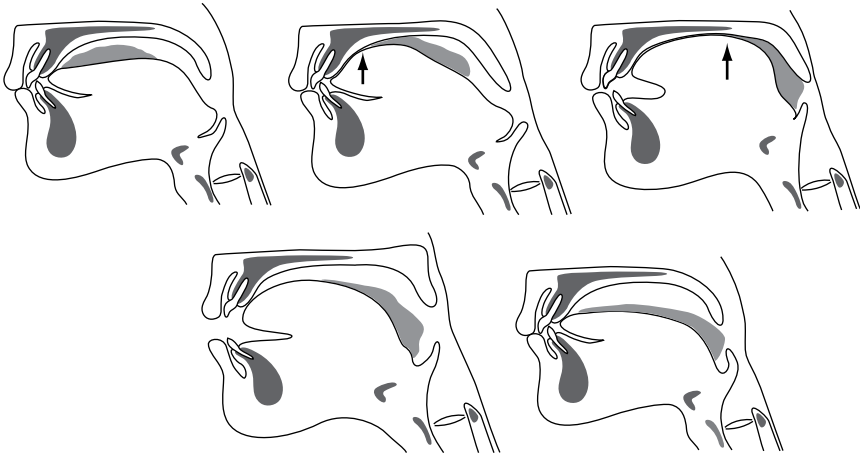


Fig. 4. Diagram of stage II transport based on a videofluorographic recording. The tongue squeezes the bolus backward along the palate, through the fauces, and into the pharynx when the upper and lower teeth are closest together and during early jaw opening phase (*first three frames*). The bolus head reaches the valleculae while food processing continues (*last two frames*).

the food bolus through the pharynx and UES to the esophagus; and (2) airway protection—insulating the larynx and trachea from the pharynx during food passage to prevent the food from entering the airway.

During the pharyngeal stage, the soft palate elevates and contacts the lateral and posterior walls of the pharynx, closing the nasopharynx at about the same time that the bolus head comes into the pharynx (Fig. 5). Soft palate elevation prevents bolus regurgitation into the nasal cavity. The base of the tongue retracts, pushing the bolus against the pharyngeal walls (see Fig. 5). The pharyngeal constrictor muscles contract sequentially from the top to the bottom, squeezing the bolus downward. The pharynx also shortens vertically to reduce the volume of the pharyngeal cavity.

Safe bolus passage in the pharynx without aspirating food is critical in human swallowing. There are several airway protective mechanisms preventing aspiration of the foreign materials to the trachea before or during swallowing. The vocal folds close to seal the glottis (space between the vocal folds), and the arytenoids tilt forward to contact the epiglottic base before opening of the UES [16,17]. The hyoid bone and larynx are pulled upward and forward by contraction of the suprahyoid muscles and thyrohyoid muscle. This displacement tucks the larynx under the base of the tongue. The epiglottis tilts backward to seal the laryngeal vestibule. The mechanism of the epiglottic tilting in human swallowing remains unclear but is probably related to hyolaryngeal elevation, pharyngeal constriction, bolus movement, and tongue-base retraction [18].

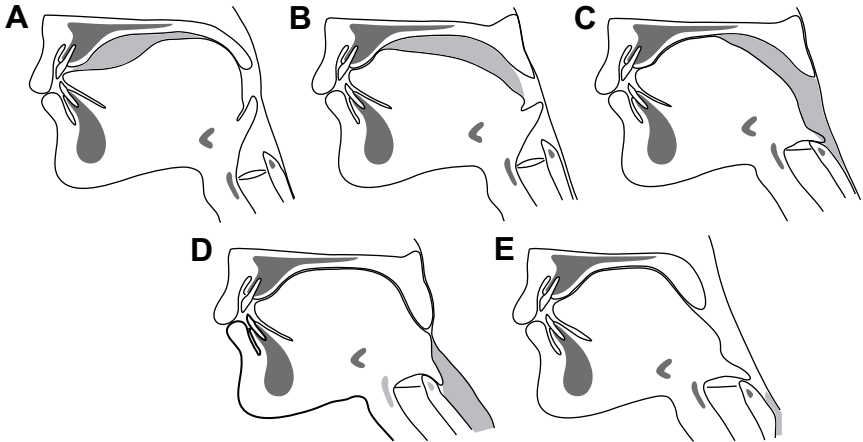


Fig. 5. Diagram of normal swallowing of a liquid bolus based on a videofluorographic recording. (A) The bolus is held between the anterior surface of the tongue and hard palate, in a “swallow-ready” position (end of oral-preparatory stage). The tongue presses against the palate in front of and behind the bolus to prevent spillage. (B) The bolus is propelled from the oral cavity to the pharynx through the fauces (oral-propulsive stage). The anterior tongue pushes the bolus against the hard palate just behind the upper incisors while the posterior tongue drops away from the palate. (C–D) Pharyngeal stage. (C) The soft palate elevates, closing off the nasopharynx. The area of tongue–palate contact spreads posteriorly, squeezing the bolus into the pharynx. The larynx is displaced upward and forward as the epiglottis tilts backward. (D) The UES opens. The tongue base retracts to contact the pharyngeal wall, which contracts around the bolus, starting superiorly and then progressing downward toward the esophagus. (E) The soft palate descends and the larynx and pharynx reopen. The UES returns to its usual closed state after the bolus passes.

Opening of the UES is essential for the bolus entry into the esophagus. The UES consists of the inferior pharyngeal constrictor muscles, cricopharyngeus muscle, and the most proximal part of the esophagus. The UES is closed at rest by tonic muscle contraction [19,20]. Three important factors contribute to UES opening: (1) relaxation of the cricopharyngeus muscle—this relaxation normally precedes opening of the UES or arrival of the bolus; (2) contraction of the suprahyoid muscles and thyrohyoid muscles—these muscles pull the hyolaryngeal complex forward, opening the sphincter; and (3) the pressure of the descending bolus—this pressure distends the UES, assisting its opening [21]. The most important of these mechanisms is the active opening process, making the opening of the UES different from other sphincters such as the external urethral sphincter, which opens passively (the urethral sphincter relaxes and is pushed open by the descending fluid bolus).

#### *Esophageal stage*

The esophagus is a tubular structure running from the lower part of the UES to the lower esophageal sphincter (LES). The LES is also tensioned at



rest to prevent regurgitation from the stomach. It relaxes during a swallow and allows bolus passage to the stomach. The cervical esophagus (upper one third) is mainly composed of striated muscle, but the thoracic esophagus (lower two thirds) is smooth muscle. Bolus transport in the thoracic esophagus is different from that in the pharynx because it is true peristalsis regulated by the autonomic nervous system. After the food bolus enters the esophagus, passing the UES, a peristalsis wave carries the bolus down to stomach through the LES. The peristaltic wave consists of two main parts: an initial wave of relaxation that accommodates the bolus, followed by a wave of contraction that propels it. Gravity, in upright positions, assists peristalsis.

#### *Bolus location at swallow initiation in normal swallows*

The position of the head of the bolus relative to the time of pharyngeal swallow onset is a measure of swallow elicitation. The point at which the radiographic shadow of the ramus of the mandible crosses the pharyngeal surface of the tongue is commonly used as a marker for this measurement. It was initially thought that the pharyngeal swallow was normally triggered when the bolus head passed the fauces, as observed on videofluoroscopy [3]. When the bolus head passed the lower border of the mandible more than 1 second before the swallow initiation, it was classified as delayed swallow initiation. Delayed swallow initiation is considered an important finding because the airway is open when the bolus approaches the larynx.

Recent studies, however, have revealed that preswallow bolus entry into the pharynx also occurs in healthy individuals when drinking liquids [22–24]. Furthermore, as described previously, during eating of solid food, chewed bolus is aggregated in the oropharynx or valleculae before swallowing. Bolus position at swallow initiation is now known to be variable in normal eating and swallowing. This variability is especially true when consuming a food that has both liquid and solid phases. Saitoh and colleagues [15] demonstrated that in healthy young adults eating a food made up of soft solid and thin liquid components, the leading edge (liquid component) of the food often entered the hypopharynx before swallowing. As seen in Fig. 6, liquid enters the hypopharynx during chewing and approaches the laryngeal aditus at a time when the larynx remains open.

The location of the bolus at swallow initiation is altered by sequential swallowing of liquid [22,25–28]. The bolus head often reaches the valleculae before pharyngeal swallow initiation, especially when the larynx remains closed between swallows.

#### *Coordination among eating, swallowing, and breathing*

Eating, swallowing, and breathing are tightly coordinated. Swallowing is dominant to respiration in normal individuals [29–31]. Breathing ceases

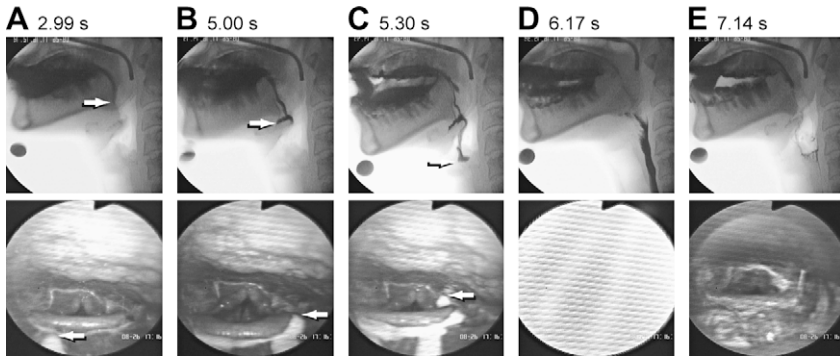


Fig. 6. Images of bolus entry into the pharynx while eating food with liquid and semisolid phases. Selected images from concurrent videofluorographic recordings (*top panel*) and fiberoptic endoscopic examination (*bottom panel*) of a normal subject consuming corned-beef hash and liquid barium. Numbers above the images indicate the time in seconds from the start of the recording. Arrows on the images indicate the leading edge of the barium. The liquid component enters the (A) valleculae, (B) hypopharynx, and (C) piriform sinus before (D) swallow initiation while the solid phase is being chewed in the oral cavity. There is no laryngeal penetration or aspiration (E).

briefly during swallowing not only because of the physical closure of the airway by elevation of the soft palate and tilting of the epiglottis but also because of neural suppression of respiration in the brainstem [30]. When drinking a liquid bolus, swallowing usually starts during the expiratory phase of breathing. The respiratory pause continues for 0.5 to 1.5 seconds during swallowing, and respiration usually resumes with expiration [32–34]. This resumption is regarded as one of the mechanisms that prevents inhalation of food remaining in the pharynx after swallowing [35]. When performing sequential swallows while drinking from a cup, respiration can resume with inspiration [36].

Eating solid food also alters the respiratory rhythm. The rhythm is perturbed with onset of mastication. Respiratory cycle duration decreases during mastication, but increases with swallowing [31,37,38]. The “exhale—swallow—exhale” temporal relationship persists during eating; however, respiratory pauses are longer, often beginning substantially before swallow onset [11,38,39].

### Abnormal eating and swallowing

Dysphagia (abnormal swallowing) can result from a wide variety of diseases and disorders (Box 1) [40,41]. Functional or structural deficits of the oral cavity, pharynx, larynx, esophagus, or esophageal sphincters can cause dysphagia. Dysphagia may lead to serious complications, including dehydration, malnutrition, pneumonia, or airway obstruction. In dysphagia

**Box 1. Diseases and disorders causing dysphagia***Neurologic disorders and stroke*

Cerebral infarction  
 Brain-stem infarction  
 Intracranial hemorrhage  
 Parkinson's disease  
 Multiple sclerosis  
 Motor neuron disease  
 Poliomyelitis  
 Myasthenia gravis  
 Dementias

*Structural lesions*

Thyromegaly  
 Cervical hypertosis  
 Congenital web  
 Zenker's diverticulum  
 Ingestion of caustic material  
 Neoplasm

*Psychiatric disorders*

Psychogenic dysphagia

*Connective tissue diseases*

Polymyositis  
 Muscular dystrophy

*Iatrogenic causes*

Surgical resection  
 Radiation fibrosis  
 Medications

---

*From* Palmer JB, Monahan DM, Matsuo K. Rehabilitation of patients with swallowing disorders. In: Braddom R, editor. Physical medicine and rehabilitation. Philadelphia: Elsevier; 2006. p. 603; with permission.

rehabilitation, clinicians consider how a given abnormality affects bolus passage and airway protection.

*Structural abnormalities*

Structural abnormalities can be congenital or acquired. Cleft lip and palate is a congenital structural abnormality that hampers labial control for sucking, decreases the oral suction, and causes insufficiency of

velopharyngeal closure with nasal regurgitation. Mastication can be impaired by the undergrowth of the maxilla and malalignment of the teeth.

Cervical osteophytes are bony outgrowths from the cervical vertebrae that commonly occur in the elderly. They may narrow the food pathway and direct the bolus toward the airway (Fig. 7) [42]. Diverticulae can occur in the pharynx or esophagus. Zenker's diverticulum is a pulsion diverticulum of the hypopharynx that occurs at a weak spot in the muscular wall. Its entrance is located just above the cricopharyngeus muscle, but the body of the pouch can extend much lower [43]. The bolus can enter the diverticulum and be regurgitated to the pharynx, which may result in coughing or aspiration.

Webs or strictures may occur in the pharynx, esophagus, or sphincters. These abnormalities can obstruct bolus passage and are usually more symptomatic with solid foods than with liquids. A common site for narrowing is the UES. Failure to open the UES may be structural (due to a web or stricture) or functional (due to weakness of the muscles that open the UES) [44]. It is difficult to differentiate these conditions, and empiric dilatation is recommended. Stricture is common in the body of the esophagus and is often related to gastroesophageal reflux disease. It is important to consider esophageal carcinoma in the differential diagnosis, because this disease is serious and treatment can improve survival and quality of life.

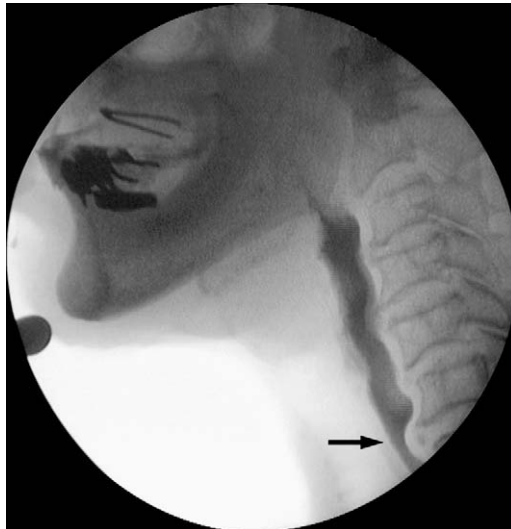

Fig. 7. A partially obstructive C6-7 anterior osteophyte (*arrow*) impinges on the column of barium, narrowing the lumen by more than 50%.

### *Functional abnormality*

Impairments affecting the jaw, lips, tongue, or cheek can hamper the oral phase or food processing. Reduced closing pressure of the lips may lead to drooling. Weak contraction of the tongue and soft palate can cause premature leakage of the bolus into the pharynx, especially with liquids. In weakness of the buccal or labial muscles, food can be trapped in the buccal or labial sulci (between the lower teeth and the cheeks or gums, respectively). Tongue dysfunction produces impaired mastication, bolus formation, and bolus transport, which usually result from tongue weakness or incoordination, but sensory impairments can produce similar effects, including excessive retention of food in the oral cavity after eating and swallowing (Fig. 8).

Loss of teeth reduces masticatory performance. When chewing is prolonged due to missing teeth, particle size of the triturated bolus becomes larger due to lower efficiency of mastication [45]. Xerostomia hampers food processing, bolus formation, and bolus transport during eating. Chemoradiation therapy for head and neck cancer often causes delayed swallow initiation, decreased pharyngeal transport, and ineffective laryngeal protection [46].

Dysfunction of the pharynx can produce impaired swallow initiation, ineffective bolus propulsion, and retention of a portion of the bolus in the pharynx after swallowing. Insufficient velopharyngeal closure may result in nasal regurgitation and reduce pharyngeal pressure in swallow, hampering transport through the UES. Weakness of tongue-base retraction or the pharyngeal constrictor muscles can render inadequate the force of pharyngeal propulsion, resulting in retention of all or part of the bolus in the pharynx (usually the valleculae and pyriform sinuses) after swallowing. Incomplete tilting of the epiglottis may obstruct bolus propulsion, especially with higher viscosity boluses, resulting in retention in the valleculae.

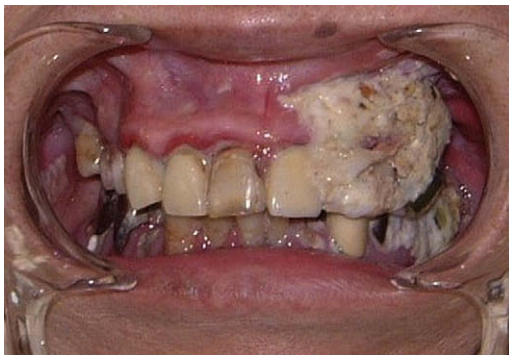


Fig. 8. Food debris retained in the left the buccal sulcus in the mouth due to buccal muscle weakness and sensory deficits caused by a right hemisphere stroke.

Impaired opening of the UES can cause partial or even total obstruction of the food passageway, with retention in the piriform sinuses and hypopharynx, increasing risk of aspiration after the swallow. Insufficient UES opening can be caused by increased stiffness of the UES, as in fibrosis or inflammation, or by failure to relax the sphincter musculature, as noted earlier. Weakness of the anterior suprahyoid muscles can impair opening of the UES, because these muscles normally pull the sphincter open during swallowing.

Esophageal dysfunction is common and often asymptomatic. Esophageal motor disorders include conditions of hyperactivity (eg, esophageal spasm), hypoactivity (eg, weakness), or incoordination of the esophageal musculature [47]. Any of these conditions can lead to ineffective peristalsis, with retention of material in the esophagus after swallowing. Retention can result in regurgitation of material from the esophagus back into the pharynx, with risk of aspirating the regurgitated material. Esophageal motor disorders are sometimes provoked by gastroesophageal reflux disease and, in some cases, can respond to treatment with proton pump inhibitors.

#### *Airway protection—penetration and aspiration*

Airway protection is critical to swallowing, and its failure can have serious consequences. Laryngeal penetration occurs when passage of the material transported from the mouth or regurgitated from the esophagus enters the larynx above the vocal folds. In contrast, aspiration is defined as passage of material through the vocal folds (Fig. 9). Laryngeal penetration is sometimes observed in normal individuals. Aspiration of microscopic

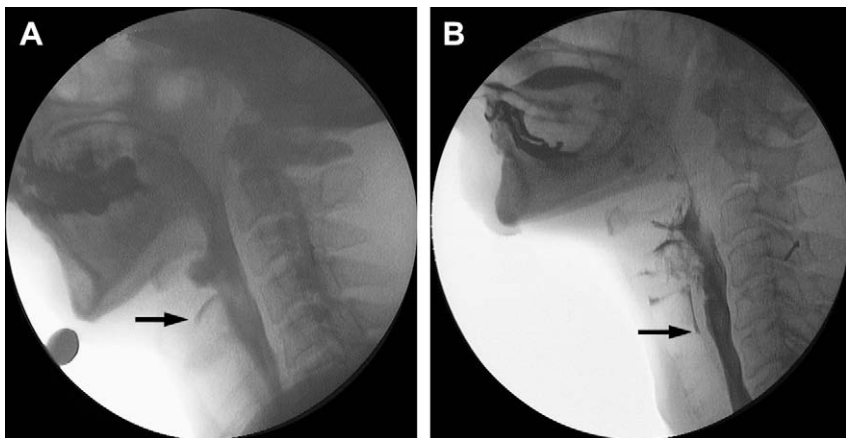


Fig. 9. Videofluorographic images of (A) laryngeal penetration and (B) aspiration in dysphagic individuals swallowing liquid barium. Arrows indicate the leading edge of the barium in the airway.

quantities also occurs in normal individuals; however, aspiration that is visible on fluoroscopy or endoscopy is pathologic and associated with increased risk of aspiration pneumonia or airway obstruction [48]. Aspiration can occur before, during, or after swallowing. Clinicians should consider the mechanism of aspiration when it is observed on fluoroscopy or endoscopy. Impairments of airway protection can result from reduced hyolaryngeal elevation, impaired epiglottic tilt, incomplete closure of the laryngeal vestibule, or inadequate vocal fold closure due to weakness, paralysis, or anatomic fixation. These impairments can lead to aspiration, usually during the swallow. Aspiration before the swallow is commonly caused by premature entry of liquids into the pharynx (due to impaired containment in the oral cavity) or by delayed onset of laryngeal closure after a bolus is propelled into the pharynx. Aspiration after the swallow is usually due to accumulated residue in the pharynx after the swallow. Material may be inhaled when breathing resumes after the swallow.

The consequences of aspiration are highly variable, ranging from no discernable effect to airway obstruction or severe aspiration pneumonia. The normal response to aspiration is strong reflex coughing or throat clearing; however, laryngeal sensation is often abnormal in individuals who have severe dysphagia [49]. Silent aspiration, or aspiration in the absence of visible response, has been reported in 25% to 30% of patients referred for dysphagia evaluations [49–51]. Several factors determine the effect of aspiration in a given individual, including the quantity of the aspirate, the depth of the aspiration material in the airway, the physical properties of the aspirate (acidic material is most damaging to the lung, producing chemical pneumonitis), and the individual's pulmonary clearance mechanism [52]. Poor oral hygiene can increase the bacterial load in the aspirate, increasing the risk of bacterial pneumonia.

## References

- [1] Jones B, editor. Normal and abnormal swallowing: imaging in diagnosis and therapy. 2nd edition. New York: Springer-Verlag; 2003.
- [2] Dodds WJ, Stewart ET, Logemann JA. Physiology and radiology of the normal oral and pharyngeal phases of swallowing [see comments]. *AJR Am J Roentgenol* 1990;154(5): 953–63.
- [3] Logemann JA. Evaluation and treatment of swallowing disorders. 2nd edition. Austin (TX): Pro-Ed; 1998.
- [4] Palmer JB, Rudin NJ, Lara G, et al. Coordination of mastication and swallowing. *Dysphagia* 1992;7(4):187–200.
- [5] Hiimae KM, Palmer JB. Food transport and bolus formation during complete feeding sequences on foods of different initial consistency. *Dysphagia* 1999;14(1):31–42.
- [6] Dua KS, Ren J, Bardan E, et al. Coordination of deglutitive glottal function and pharyngeal bolus transit during normal eating. *Gastroenterology* 1997;112(1):73–83.
- [7] Hiimae KM. Feeding in mammals. In: Schwenk K, editor. Feeding: form, function, and evolution in tetrapod vertebrates. 1st edition. San Diego (CA): Academic Press; 2000. p. 411–48.

- [8] Matsuo K, Hiiemae KM, Palmer JB. Cyclic motion of the soft palate in feeding. *J Dent Res* 2005;84(1):39–42.
- [9] Buettner A, Beer A, Hannig C, et al. Observation of the swallowing process by application of videofluoroscopy and real-time magnetic resonance imaging—consequences for retronasal aroma stimulation. *Chem Senses* 2001;26(9):1211–9.
- [10] Hodgson M, Linforth RS, Taylor AJ. Simultaneous real-time measurements of mastication, swallowing, nasal airflow, and aroma release. *J Agric Food Chem* 2003;51(17):5052–7.
- [11] Palmer JB, Hiiemae KM. Eating and breathing: interactions between respiration and feeding on solid food. *Dysphagia* 2003;18(3):169–78.
- [12] Palmer JB, Hiiemae KM, Liu J. Tongue-jaw linkages in human feeding: a preliminary videofluorographic study. *Arch Oral Biol* 1997;42(6):429–41.
- [13] Mioche L, Hiiemae KM, Palmer JB. A postero-anterior videofluorographic study of the intra-oral management of food in man. *Arch Oral Biol* 2002;47(4):267–80.
- [14] Palmer JB. Bolus aggregation in the oropharynx does not depend on gravity. *Arch Phys Med Rehabil* 1998;79(6):691–6.
- [15] Saitoh E, Shibata S, Matsuo K, et al. Chewing and food consistency: effects on bolus transport and swallow initiation. *Dysphagia* 2007;22(2):100–7.
- [16] Shaker R, Dodds WJ, Dantas RO, et al. Coordination of deglutitive glottic closure with oropharyngeal swallowing. *Gastroenterology* 1990;98(6):1478–84.
- [17] Ohmae Y, Logemann JA, Kaiser P, et al. Timing of glottic closure during normal swallow. *Head Neck* 1995;17(5):394–402.
- [18] Logemann JA, Kahrilas PJ, Cheng J, et al. Closure mechanisms of laryngeal vestibule during swallow. *Am J Physiol* 1992;262(2 Pt 1):G338–344.
- [19] Cook IJ, Dodds WJ, Dantas RO, et al. Opening mechanisms of the human upper esophageal sphincter. *Am J Physiol* 1989;257(5 Pt 1):G748–59.
- [20] Ertekin C, Aydogdu I. Electromyography of human cricopharyngeal muscle of the upper esophageal sphincter. *Muscle Nerve* 2002;26(6):729–39.
- [21] Shaw DW, Cook IJ, Gabb M, et al. Influence of normal aging on oral-pharyngeal and upper esophageal sphincter function during swallowing. *Am J Physiol* 1995;268(3 Pt 1):G389–96.
- [22] Daniels SK, Foundas AL. Swallowing physiology of sequential straw drinking. *Dysphagia* 2001;16(3):176–82.
- [23] Martin-Harris B, Brodsky MB, Michel Y, et al. Delayed initiation of the pharyngeal swallow: normal variability in adult swallows. *J Speech Lang Hear Res* 2007;50(3):585–94.
- [24] Stephen JR, Taves DH, Smith RC, et al. Bolus location at the initiation of the pharyngeal stage of swallowing in healthy older adults. *Dysphagia* 2005;20(4):266–72.
- [25] Chi-Fishman G, Stone M, McCall GN. Lingual action in normal sequential swallowing. *J Speech Lang Hear Res* 1998;41(4):771–85.
- [26] Chi-Fishman G, Sonies BC. Motor strategy in rapid sequential swallowing: new insights. *J Speech Lang Hear Res* 2000;43(6):1481–92.
- [27] Chi-Fishman G, Sonies BC. Kinematic strategies for hyoid movement in rapid sequential swallowing. *J Speech Lang Hear Res* 2002;45(3):457–68.
- [28] Daniels SK, Corey DM, Hadskey LD, et al. Mechanism of sequential swallowing during straw drinking in healthy young and older adults. *J Speech Lang Hear Res* 2004;47(1):33–45.
- [29] Nishino T, Yonezawa T, Honda Y. Effects of swallowing on the pattern of continuous respiration in human adults. *Am Rev Respir Dis* 1985;132(6):1219–22.
- [30] Nishino T, Hiraga K. Coordination of swallowing and respiration in unconscious subjects. *J Appl Physiol* 1991;70(3):988–93.
- [31] McFarland DH, Lund JP. Modification of mastication and respiration during swallowing in the adult human. *J Neurophysiol* 1995;74(4):1509–17.
- [32] Selley WG, Flack FC, Ellis RE, et al. Respiratory patterns associated with swallowing: part 1. The normal adult pattern and changes with age. *Age Ageing* 1989;18(3):168–72.
- [33] Klahn MS, Perlman AL. Temporal and durational patterns associating respiration and swallowing. *Dysphagia* 1999;14(3):131–8.



- [34] Martin-Harris B, Brodsky MB, Michel Y, et al. Breathing and swallowing dynamics across the adult lifespan. *Arch Otolaryngol Head Neck Surg* 2005;131(9):762–70.
- [35] Shaker R, Li Q, Ren J, et al. Coordination of deglutition and phases of respiration: effect of aging, tachypnea, bolus volume, and chronic obstructive pulmonary disease. *Am J Physiol* 1992;263(5 Pt 1):G750–5.
- [36] Dozier TS, Brodsky MB, Michel Y, et al. Coordination of swallowing and respiration in normal sequential cup swallows. *Laryngoscope* 2006;116(8):1489–93.
- [37] Smith J, Wolkove N, Colacone A, et al. Coordination of eating, drinking and breathing in adults. *Chest* 1989;96(3):578–82.
- [38] Matsuo K, Hiemae KM, Gonzalez-Fernandez M, et al. Respiration during feeding on solid food: alterations in breathing during mastication, pharyngeal bolus aggregation and swallowing. *J Appl Physiol* 2008;104(3):674–81.
- [39] Charbonneau I, Lund JP, McFarland DH. Persistence of respiratory-swallowing coordination after laryngectomy. *J Speech Lang Hear Res* 2005;48(1):34–44.
- [40] Kuhlemeier KV. Epidemiology and dysphagia. *Dysphagia* 1994;9(4):209–17.
- [41] Castell DO, Donner MW. Evaluation of dysphagia: a careful history is crucial. *Dysphagia* 1987;2(2):65–71.
- [42] Di Vito J Jr. Cervical osteophytic dysphagia: single and combined mechanisms. *Dysphagia* 1998;13(1):58–61.
- [43] Ferreira LE, Simmons DT, Baron TH. Zenker's diverticula: pathophysiology, clinical presentation, and flexible endoscopic management. *Dis Esophagus* 2008;21(1):1–8.
- [44] Ferguson DD. Evaluation and management of benign esophageal strictures. *Dis Esophagus* 2005;18(6):359–64.
- [45] van der Bilt A, Olthoff LW, Bosman F, et al. The effect of missing postcanine teeth on chewing performance in man. *Arch Oral Biol* 1993;38(5):423–9.
- [46] Eisbruch A, Lyden T, Bradford CR, et al. Objective assessment of swallowing dysfunction and aspiration after radiation concurrent with chemotherapy for head-and-neck cancer. *Int J Radiat Oncol Biol Phys* 2002;53(1):23–8.
- [47] Moayyedi P, Talley NJ. Gastro-oesophageal reflux disease. *Lancet* 2006;367(9528):2086–100.
- [48] Marik PE. Aspiration pneumonitis and aspiration pneumonia. *N Engl J Med* 2001;344(9):665–71.
- [49] Garon BR, Engle M, Ormiston C. Silent aspiration: results of 1,000 videofluoroscopic swallow evaluations. *J Neurol Rehabil* 1996;10(2):121–6.
- [50] Leder SB, Sasaki CT, Burrell MI. Fiberoptic endoscopic evaluation of dysphagia to identify silent aspiration. *Dysphagia* 1998;13(1):19–21.
- [51] Smith CH, Logemann JA, Colangelo LA, et al. Incidence and patient characteristics associated with silent aspiration in the acute care setting [see comments]. *Dysphagia* 1999;14(1):1–7.
- [52] Palmer JB, Drennan JC, Baba M. Evaluation and treatment of swallowing impairments. *Am Fam Physician* 2000;61(8):2453–62.