Motricidade Orofacial em Ortodontia

Revisando conceitos (1)

Aula prática online- 20/05/23

Prof. Diana Grandi

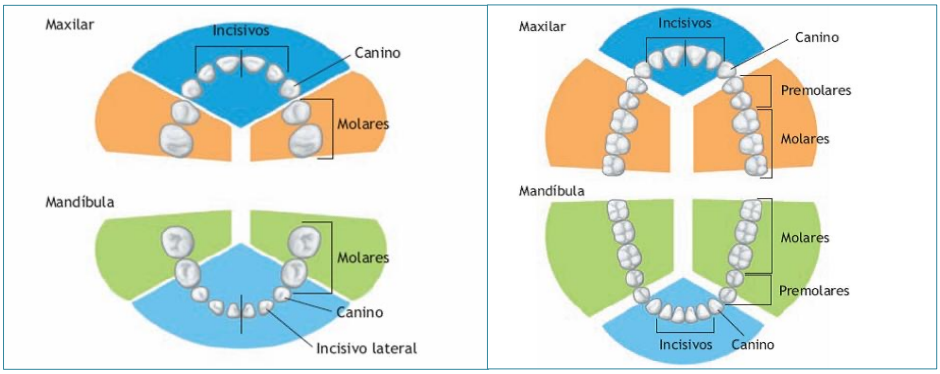

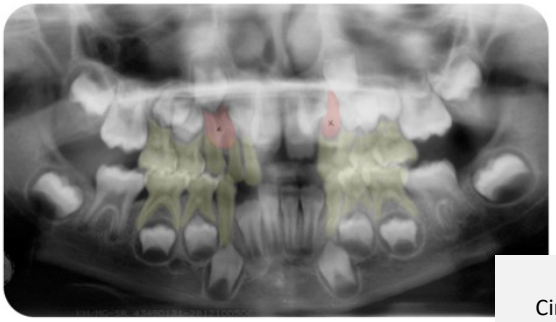

Dr. Calderón Polanco
Cirugía Oral y Máxilofacial - Madrid

Dr. Joan Pau Marcó
Clínica de Ortodoncia - Barcelona

Dr. Calderón Polanco
Cirugía Oral y Máxilofacial - Madrid

a b d c e

---

a b d c e

Diana Grandi

Diana Grandi

Diana Grandi

Diana Grandi

Diana Grandi

¿PLANO?

¿?

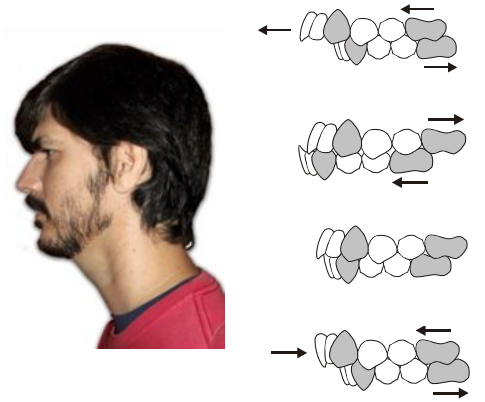

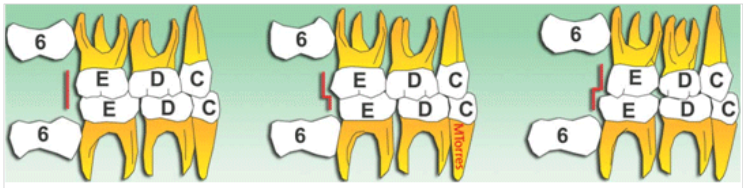

Fig. 12
Esquema de los tres tipos de planos terminales ® A. Plano terminal recto, B. escalón mesial C. Escalón distal

¿PLANO?

¿?

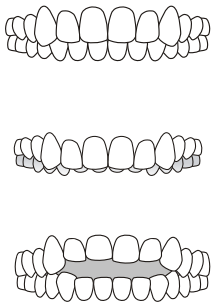

¿PLANO?

¿?

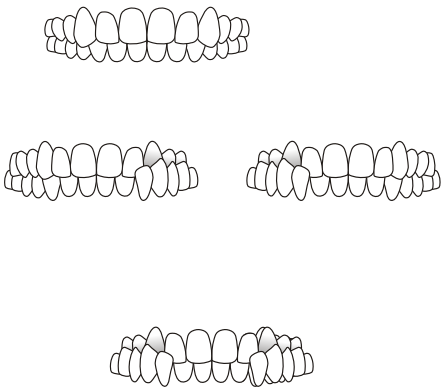

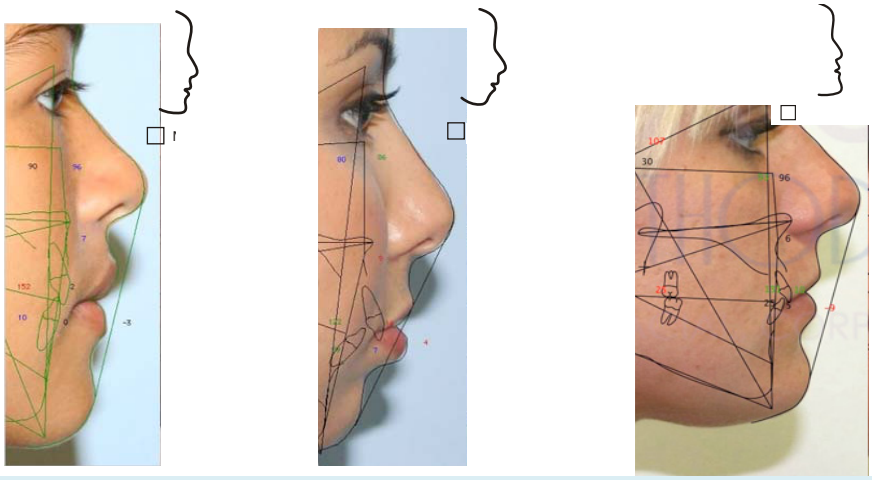

Plano estético de Ricketts:
- Menos de 2 mm de distancia a la línea: perfil RECTO
- Labio inferior por delante de la línea: perfil CONVEXO
- Labio SUPERIOR por detrás de la línea: perfil CÓNCAVO